

# Effect of Chronic Exposure to X-Ray on the Heart and Aorta in Male Albino Rats

Wifaq Jbori Albazi\* , Sina J, Al-Bazii Heba A and Al-Salman

Department of Medicine, University of Kerbala, Karbala, Iraq

## Research Article

Received date: 31/07/2017  
Accepted date: 17/08/2017  
Published date: 24/08/2017

### \*For Correspondence

Wifaq Jbori Albazi, University of Kerbala, Karbala, Iraq, Tel: 07816113430.

**E-mail:** wifaq.jbori@uokerbala.edu.iq

**Keywords:** X-ray, Heart, Oarta, Rabbits

### ABSTRACT

X-radiation and gamma radiation are both part of the electromagnetic radiation spectrum. Just as we say that matter is made up of atoms, electromagnetic radiation is 'madeup' of photons. The energy associated with gamma radiation and X-radiation is high enough to break atomic and molecular bonds (that is, to ionize atoms), producing changes in matter including living cells.

## INTRODUCTION

X-radiation and gamma radiation are both part of the electromagnetic radiation spectrum. Just as we say that matter is made up of atoms, electromagnetic radiation is 'madeup' of photons. The energy associated with gamma radiation and X-radiation is high enough to break atomic and molecular bonds (that is, to ionize atoms), producing changes in matter including living cells. This high-energy end of the spectrum is referred to as 'ionizing radiation' [1]. Exposure to ionizing radiation brings about effects that involve all systems of the organism. The type and frequency of such effects are strongly dependent on the dose of radiation absorbed and on the condition of exposure [2].

Irradiation is the conventional treatment modality for cancer patients. However, besides its cytotoxic effects on malignant cells it might also affect the biology of surviving cells [3]. Radiotherapy is a useful treatment for oral cancer in combination with surgery. However, irrecoverable damage occurs to intact bone tissue after therapeutic irradiation depending on the quantity of ionizing radiation used [4].

Unborn babies are less sensitive during some stages of pregnancy than others. However, fetuses are particularly sensitive to radiation during their early development, between weeks 2 and 18 of pregnancy. The health consequences can be severe, even at radiation doses too low to make the mother sick. Such consequences can include stunted growth, deformities, abnormal brain function, or cancer that may develop sometime later in life [5]. X-ray inspection is a commonly employed tool used to gauge the quality of solder connections on surface mounted BGA packaged devices on circuit boards. It has been well established that semiconductor ICs can suffer damage from (dis)charging effects caused by X-ray energy [6]. X-ray devices are important tools in various areas of modern research. The X-rays produced by such equipment, however, can pose a hazard to human health. For this reason, special precautions must be observed when these devices are used [7]. Irradiation of embryonic cells may lead to effects which include immediate cell death, nuclear pycnosis after a few hours, congenital anomalies cell death, malignancies which may appear after a variably long period of latency [8]. Epiphysial cartilage plates, severe alteration of the epiphysial cartilage was a consistent feature in almost all of the irradiated animals [9].

Also notice parturient abnormal fetuses with small head and mental retardation in women which exposure to radiation during gestation [10]. Notice present nodules smaller than 0.5 mm in diameter and discrete foci of the thyroid tissue which differed only slightly from surrounding parenchyma [11]. After 20 days of exposure to mobile phone, it produced a significant increase in the brain tissue [12]. Ten days after irradiation the number of spermatogonia is greatly reduced, especially in the tubules close to the testicular surface [13].

## MATERIALS AND METHODS

This study was conducted on laboratory animals, which ranged ages between 4-5 months, ranged weights between 200-250 gm (Figure 1).



**Figure 1.** Explain adapted rats.



**Figure 2.** X-ray apparatus used in radiation the animal.

Leave the rats in the laboratory until they reach the amount of radiation issued by the radiographic device to the dose required a 300 kV, where the dose given to each patient vary by User or place exhibition of rays, then rats are taken and placed in a remote laboratory somewhere and after cleaning cages and washed with alcohol and switch Band returned the next day and subjected to the required amount of radiation and so on. After 30 days of irradiation were killed rats textured chloroform, and explained and kept the sample after the eradication of the animal in 10% formalin. To check the affected rats X-ray tissue sections in medical Sadr City and had attended the series of Alalmilit depending an elegant method described by Presnell and Schreibman (**Figure 2**).

## RESULTS AND DISCUSSION

The treated animal group was exposed to x-ray for 30 days showed behavior disorder like anaroxia, hair loss with depression and white spots on the tail (**Figures 3 and 4**).

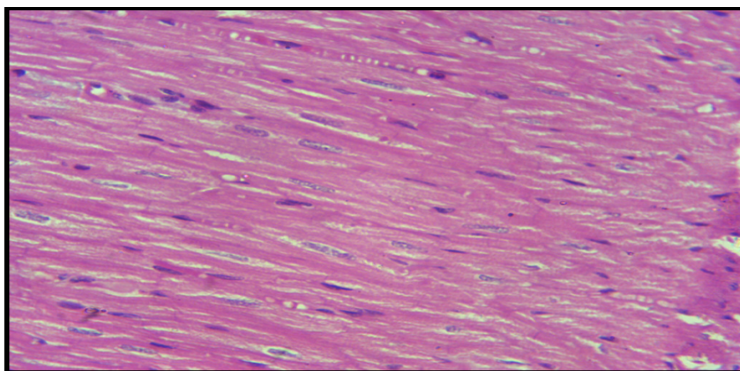


**Figure 3.** Shows swelled the body of animals exposed for X-ray for period one month.

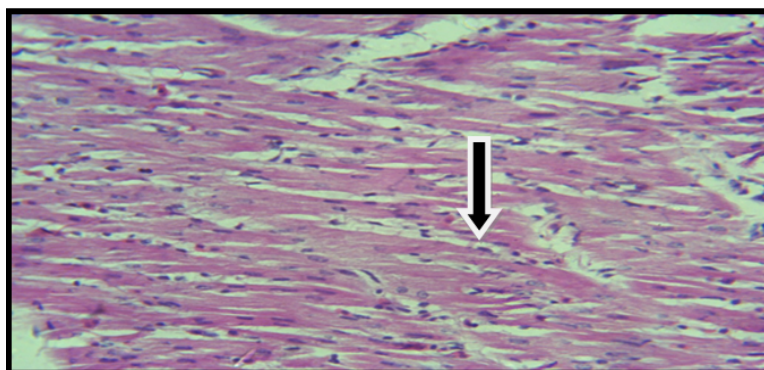


**Figure 4.** Shows white spot on tail skin of treated groups.

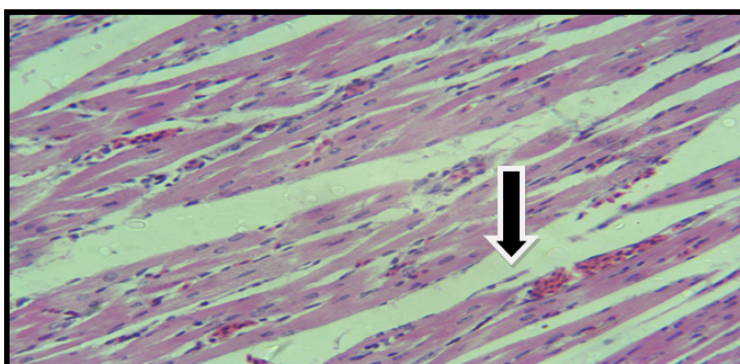
Histological section of heart of treated group showed damage of muscle fiber, disappear intercalated disc and congestion with inflammatory cells infiltration as compared with control **Figure 5** coinciding with these results other authors found that. Furthermore, some researchers (observed that x-ray induced thickening in the endothelium with adhere damaged cells and foamy cells found in the sub endothelial layer as compared with control **Figures 6-15** <sup>[14-17]</sup>.



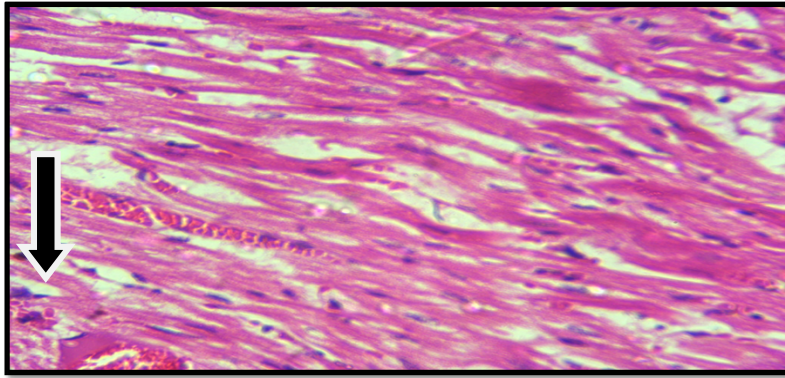
**Figure 5.** Histological section in the heart of control group shows normal structure (E&H 40x).



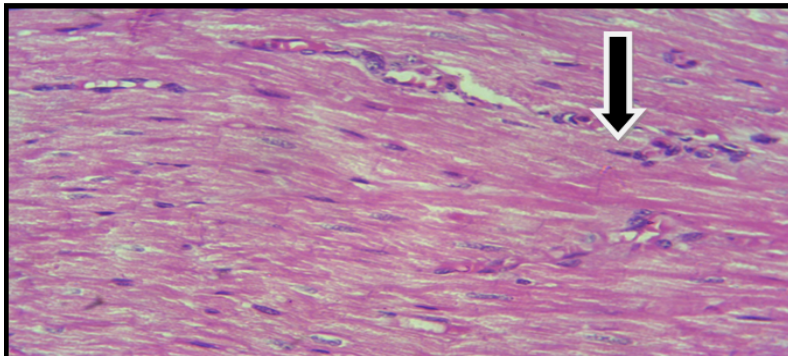
**Figure 6.** Histopathological section in the treated group shows cardiac cells (H&E40x).



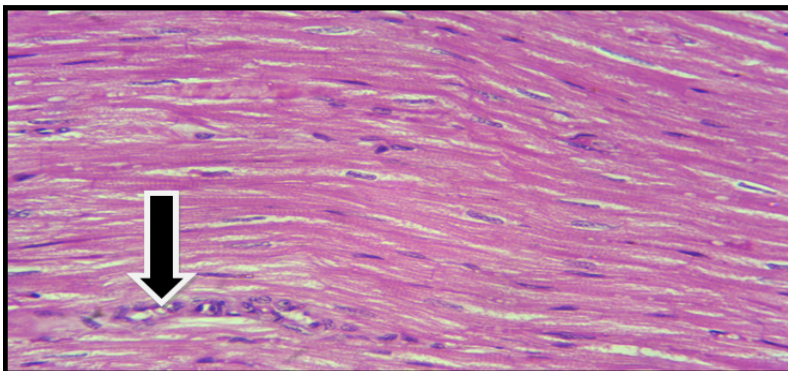
**Figure 7.** Histopathological section in treated group shows cardiac cell necrosis with hemorrhage (H&E40x).



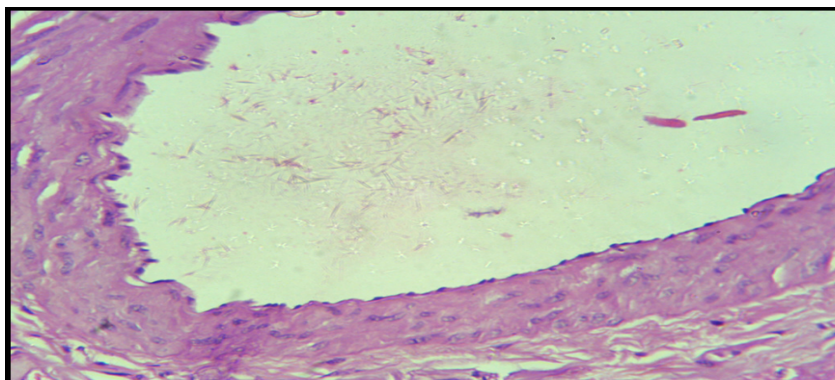
**Figure 8.** Histopathological section in treated group shows damage in cardiac cell with hemorrhage (H&E40x).



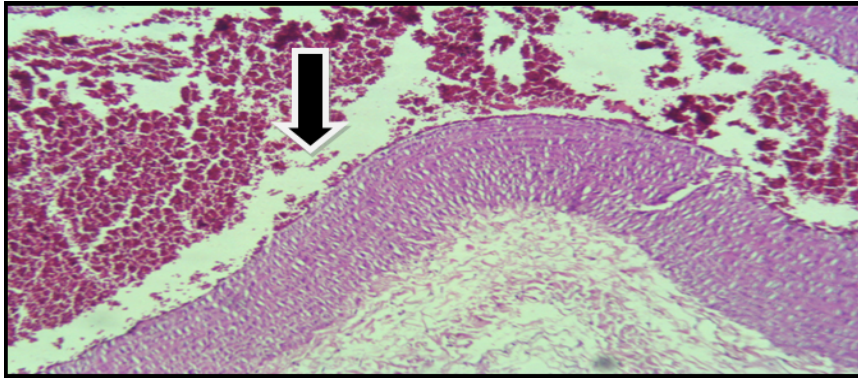
**Figure 9.** Histopathological section in treated group shows inflammation in muscle fiber of heart represent in present inflammatory cells (H&E40x).



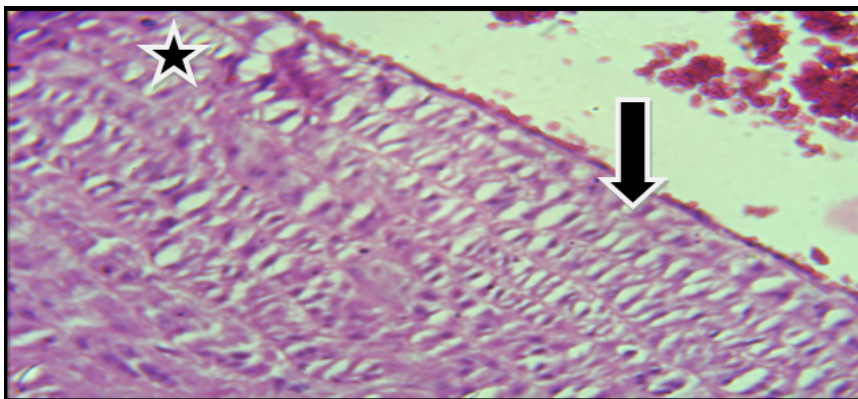
**Figure 10.** Histopathological section in treated group shows inflammation in muscle fiber of heart represent in present inflammatory cells (H&E40x).



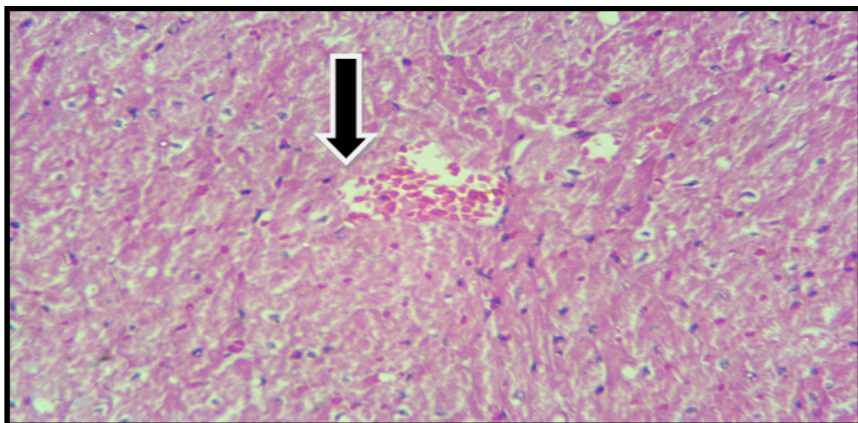
**Figure 11.** Histopathological section in control group shows normal structure of large artery (H&E40x).



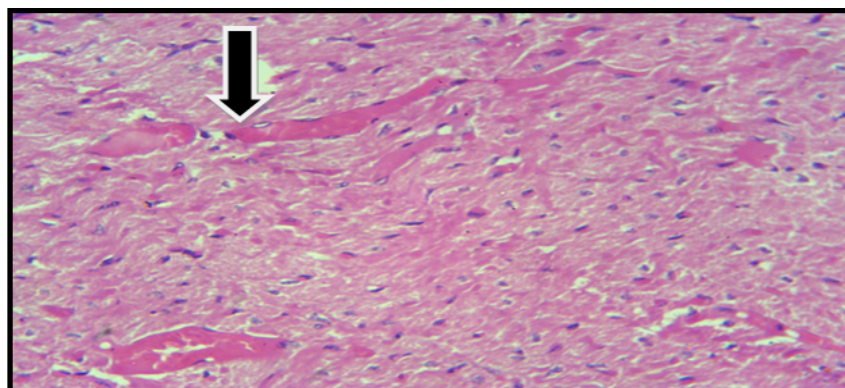
**Figure 12.** Histopathological section in treated group shows thickening in the endothelium with adhere damaged cells (H&E40x).



**Figure 13.** Histopathological section in treated group shows thickening in the endothelium with adhere damaged cells and foamy cells found in the sub-endothelial layer (H&E40x).



**Figure 14.** Histopathological section in treated group shows damaged with hemorrhage in sub-endothelial layer (H&E40x).



**Figure 15.** Histopathological section in treated group shows damaged cells with hemorrhage in sub-endothelial layer (H&E40x).

## CONCLUSION

This study was designed to investigate the effect of the X-ray in the cardiovascular system of adult male albino rat. Ten adult male rats were randomly divided into two groups five rats for each group, control group (T), treated group (T1) were exposed to 300 KV/2 M daily for 1 month. Histological section of heart of treated group (T1) showed damage of muscle fiber, disappear intercalated disc and congestion with inflammatory cells infiltration, comparative with control group (T), while histological section of large artery showed thickening in the endothelium with adhere damaged cells and foamy cells found in the sub endothelial layer.

## REFERENCES

1. Alpen EL. Radiation biophysic. Academic Press, New York, USA; 1990.
2. United Nations Scientific Committee on the Effect of Atomic Radiation, Report of the United Nations Scientific Committee on the Effect of Atomic Radiation. General Assembly document. 17th session, Suppl No.16 (A/5216). United Nations, N.Y. 1962.
3. Juranic ZD, et al. Effects of X-ray irradiation on the overexpression of HER-2/Erb-B2 on breast cancer cell lines. J Exp Clin Cancer Res. 2004;23:675-680.
4. Schultze-Mosgau S, et al. Expression of bone morphogenic protein2/4, transforming growth factor-beta1 and bone matrix protein expression in healing area between vascular tibia grafts and irradiated bone-experimental model of osteonecrosis. Int J Radiat Oncol Biol Phys. 2005;61:1189-1196.
5. <https://emergency.cdc.gov/radiation/pdf/prenatal.pdf>
6. Blish R. Impact of X-Ray Inspection on cypress flash memory. Cypress Semiconductor Corporation. 2008;1:1-5.
7. Jenkins, et al. Hazards in the use of x-ray analytical instrumentation. Methods and Practices. 1973;2:1-8.
8. Rugh R, et al. Low dose x-ray effects on the pre-cleavage mammalian zygote. Rad Res. 1969;37:401-414.
9. Baserga R, et al. The delayed effects of external gamma irradiation on the bones of rats. Am J Pathol. 1961;39:455-472.
10. Jeanne A, et al. Visceral obesity and breast cancer risk. Cancer. 1994;74:632-639.
11. Doniach I. Comparison of the carcinogenic effect of x-irradiation with radioactive iodine on the rats thyroid. Br J Cancer. 1956;1:67-76.
12. Sokolovic D, et al. Melatonin reduces oxidative stress induced by chronic exposure of microwave radiation from mobile phones in rat brain. J Radiat Res. 2008;49:579-586.
13. Pecora P, et al. B-glucuronidase and esterase activities of rat testis after x-ray treatment. J of Reprod and Ferti. 1946;8:0022-4251.
14. Jay K, et al. Evaluation of the effects of radiation from an x-ray baggage inspection system on microbial applied biosafety. Applied Biosafety. 2010;15:9-14.
15. Borcia C, et al. In vitro study of radiation-induced DNA damage. Romanian Reports in Physics. 2014;66:16-21.
16. Cerqueira EM, et al. Genotoxic effects of X-rays on keratinized mucosa cells during panoramic dental radiography. Dentomaxillofac Radiol. 2008;37:398-403.
17. Meo S, et al. Hazards of X-ray radiation on the quantitative and phagocytic functions of polymorphonuclear neutrophils in X-ray technicians. J Occup Health. 2006;48:88-92.