

# Visibility of Maxillary and Mandibular Anatomical Landmarks in Digital Panoramic Radiographs: A Retrospective Study

Srisha Basappa, Smitha JD, Nishath Khanum\*, Santosh Kanwar, Mahesh MS and Archana Patil

Department of Oral Medicine and Radiology, Farooqia Dental College and Hospital, Mysore, India

## Research Article

Received: 23/08/2017

Accepted: 29/08/2017

Published: 06/09/2017

### \*For Correspondence

Nishath Khanum, Department of Oral Medicine and Radiology, Farooqia Dental College and Hospital, Mysore, India,  
Tel: 0821-2494890.

**E-mail:** nishkhan7@yahoo.co.in

**Keywords:** Mandibular, Radiograph, Tomography

## ABSTRACT

**Aims:** To determine frequency, visibility and gender variation of pterygomaxillary fissure, incisive foramen, mental foramen, mandibular canal, anterior loop of mental nerve and elongated styloid process in different age groups.

**Materials and methods:** The study was conducted in 200 orthopantomographs (OPG) which was taken using digital Sirona machine. The maxillary and mandibular anatomical landmarks were analysed and scores were recorded.

**Results:** A total of 200 OPGs were analysed. Pterygomaxillary fissure was visible in 58%. Incisive foramen showed good visibility in 25%. Mental foramen showed good visibility in 77%, mandibular canal was visible in 74% on OPG. Anterior looping was perceptible in 20% of cases. Elongated styloid process was visible in 25% of cases. Gender does not exert effect on the appearance of the anatomical structures and the study also revealed significant statistical difference between visibilities of anterior looping, which was better in males as compared to females.

**Conclusion:** Orthopantomographs provided sufficient information of mental foramen and mandibular canal and are reliable to visualise pterygomaxillary fissure. But for better visualization, detection of structures like incisive foramen anterior looping and elongated styloid process for performing surgery, for implant placement in this region it may require to be replaced with three-dimensional imaging like cone-beam computed tomography.

## INTRODUCTION

Panoramic imaging is also called pan tomography. It is a technique for producing a single image of facial structures that includes both maxillary and mandibular dental arches and their supporting structures<sup>[1]</sup>. certain peculiarities of the panoramic system result in unique projection of many anatomic structures in the image<sup>[2]</sup>. This produces numerous anatomic relationships in the image that are not found in any other kind of radiographic projection. The word panoramic radiography which means an unimpeded view of an area in every required direction<sup>[3]</sup>. Placement of mandibular endosseous implants can be problematic especially in the area of neurovascular bundles. The complications, such as altered sensation, numbness and pain, often occurred if these vital structures, such as inferior alveolar nerve (IAN) and mental foramen (**Figure 1**), incisive foramen (**Figure 1**) if they are not properly identified. Hence, it is critical to determine the location and configuration of the mandibular canal (MC) and related anatomical structures so these types of damages can be minimized<sup>[4]</sup>. The mental canal (**Figure 2**) which rises from the mandibular canal and runs outward, upward and backward to open at the mental foramen has an anatomical variation called anterior loop (**Figure 3**). Prevalence of the anterior loop is quite variable in literature, occurring in between the range of 28% and 71%<sup>[5]</sup>.

While examining the posterior wall of the sinus, we also look at the zygomatic process of the maxilla and pterygomaxillary fissure (**Figure 2**). These are thin radiopaque lines produced by these structures which run roughly parallel to the posterior wall of the maxillary sinus, and may be confused with it. Destructive disease affecting the maxillary sinus may erode the posterior wall, which can be easily missed if all three lines are not identified<sup>[6]</sup>.

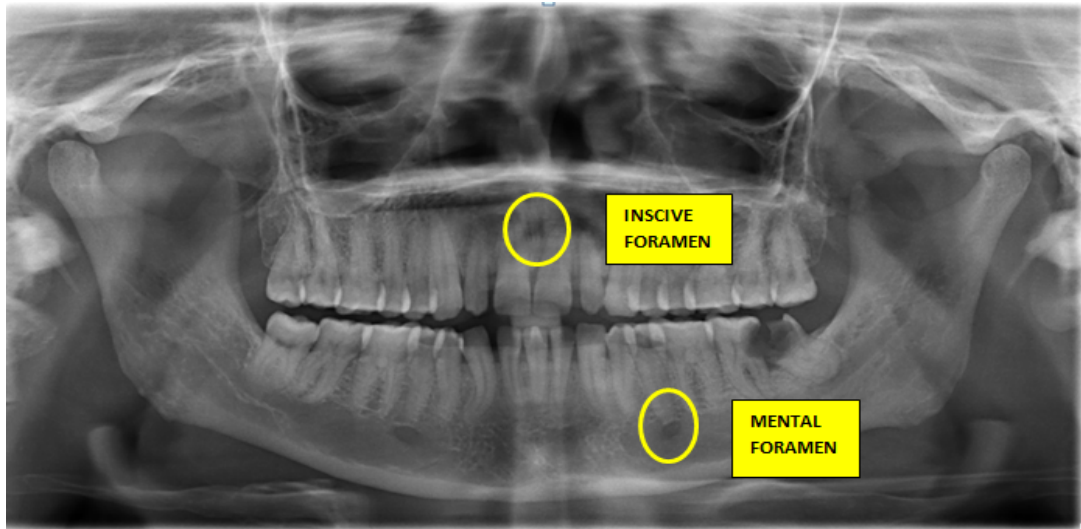


Figure 1. OPG showing incisive foramen and mental foramen.

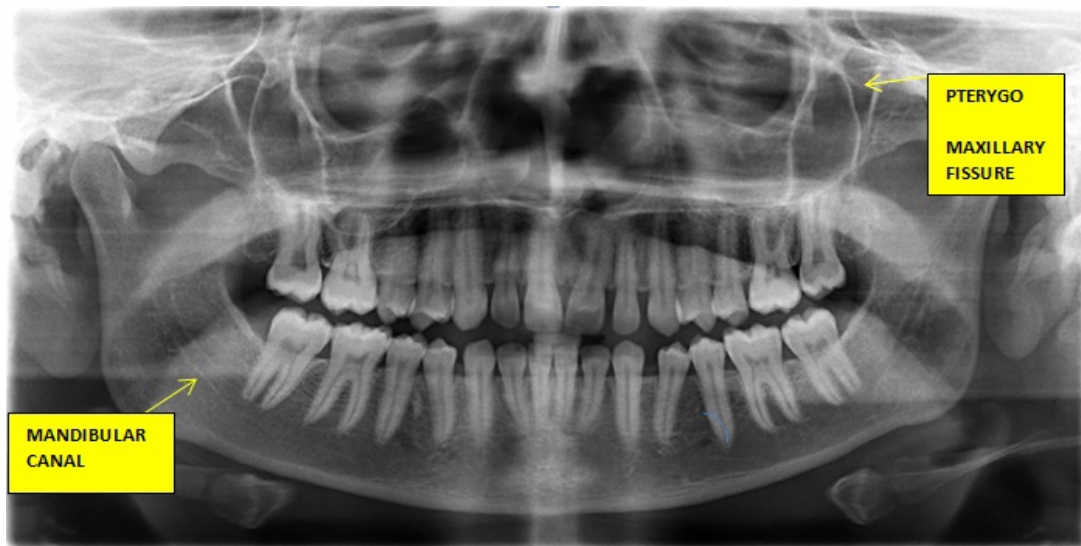

Figure 2. OPG showing mandibular canal and pterygomaxillary fissure.

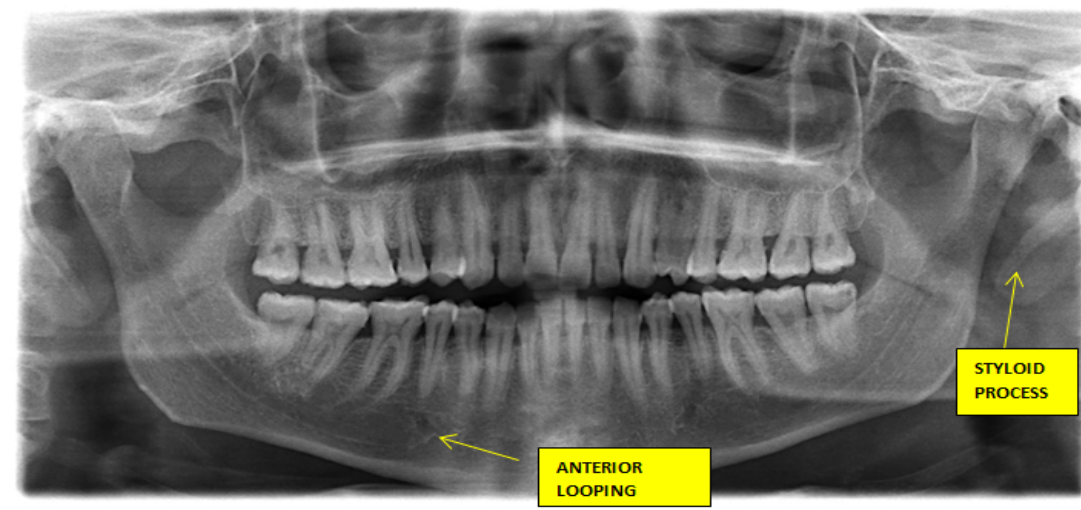


Figure 3. OPG showing styloid process and anterior looping.

## AIMS AND OBJECTIVES

1. To assess the visibility of maxillary and mandibular anatomical structures on digital radiographs.
2. To determine how frequently these structures are seen on digital orthopantomograms (OPG).

## MATERIALS AND METHODS

This study consisted of 200 randomized digital OPG which was stored as soft copies in the extra oral radiographic machine in the Department of Oral Medicine and Maxillofacial Radiology Farooqia dental college, Mysore. The radiographs were selected based on the following criteria.

### Inclusion Criteria

- Images of good quality with respect to contrast.
- Devoid of any jaw lesions and traumatic injuries in the mandible.
- Images without radiographic exposure or processing artefacts.

### Exclusion Criteria

- Poor quality radiographs.
- Presence of processing artefacts.
- Presence of jaw fracture in maxilla or mandible.
- Presence of any pathology in maxilla or mandible.

The radiographs were randomly selected between the age of 10 and 80 years. All radiographs were taken with a digital machine, SIRONA Orthophos XG 5 Ceph with the following parameters:

- Kilovoltage of 62-73 kVp
- Tube current 8-15 mA
- Time for 14.9 s

The maxillary and mandibular anatomical structures such as pterygomaxillary fissure, incisive foramen mandibular canal, anterior loop of mental nerve and mental foramen were analysed.

A four-point grading scale was used to note the visibility of these landmarks.

- Good (Above average)
- Moderate (Average)
- Poor (Below average)
- No visibility (not seen)

### Statistical Analysis

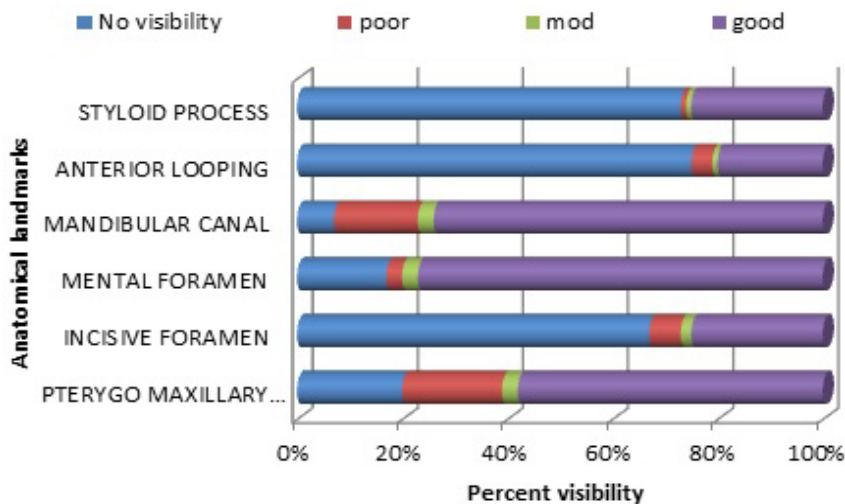
Observed data were recorded and analysed using statistical software. The observations were blinded by single and double observers and calculated using statistics which showed good agreement with both the observers.

## RESULTS

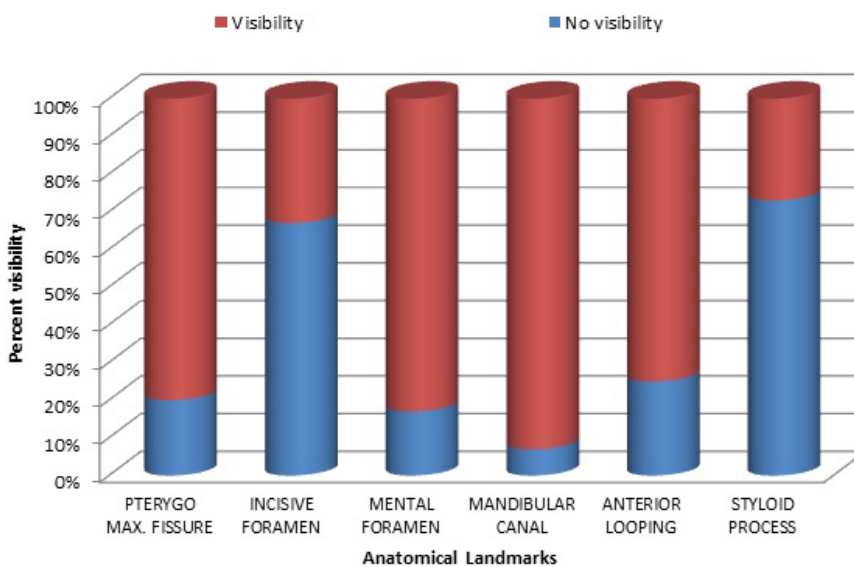
Out of 200 cases, pterygomaxillary fissure had good visibility in 58% and no visibility in 20% of cases. In 67% of the cases incisive foramen had no visibility and 25% showed good visibility. Mental foramen showed good visibility in about 77% of cases and no visibility in about 17% cases. Mandibular canal showed good visibility in about 74% of cases and no visibility in about 7% of cases. Anterior loop of the mental nerve was not seen in 75% cases and good visibility in about 20% cases 1% with moderate visibility. Elongated styloid process had good visibility in about 25%, moderate visibility in about 2% and no visibility in about 73% of cases (**Table 1**). Based on sample size and using Chi-square test, gender does not exert effect on the appearance of the anatomical structures and also revealed, significant statistical difference existed between visibility of anterior looping, which was better in males as compared to females (**Graphs 1 and 2**).

**Table 1.** Males and females sample size (200).

Anatomical Structures	No Visibility (A)	Poor Visibility (B)	Moderate Visibility (C)	Good Visibility (D)	Total Visibility (E=B+C+D)
Pterygomaxillary Fissure	40(20%)	38(19%)	6(3%)	116(58%)	160
Incisive Foramen	134(67%)	12(6%)	4(2%)	50(25%)	66
Mental Foramen	34 (17%)	6(3%)	6(3%)	154(77%)	168
Mandibular Canal	14(7%)	32(16%)	6(3%)	148(74%)	186
Anterior Looping	150(75%)	8(4%)	2(1%)	40(20%)	50
Elongated Styloid Process	146(73%)	2(1%)	2(1%)	50(25%)	54



**Graph 1.** Percent visibility in males and females.



**Graph 2.** Percent Visibility and no visibility in males and females.

## DISCUSSION

Panoramic radiography has become a commonly used imaging modality in dental practice and can be a valuable diagnostic tool in the dentist’s armamentarium. However, the panoramic image is a complex projection of the jaws with multiple superimpositions and distortions which may be exacerbated by technical errors in image acquisition. Furthermore, the panoramic radiograph depicts numerous anatomic structures outside of the jaws which may create additional interpretation challenges. Successful interpretation of panoramic radiographs begins with an understanding of the normal anatomy of the head and neck [6].

Examining the cortical outline of maxilla is a very good way to center the examination of mid face. The posterior border of maxilla extends from superior portion of pterygomaxillary fissure down to tuberosity region around the other side. Pterygomaxillary fissure itself has an inverted teardrop appearance. It is very important to identify this area on both sides of the image because maxillary sinus mucoceles and carcinomas characteristically destroy the posterior maxillary border, which is manifested as loss of pterygomaxillary fissure. Lefort fracture often is initially diagnosed by disturbances of integrity of pterygomaxillary fissure on OPG<sup>[1]</sup>.

The mental foramen is more commonly located at the summit of the second mandibular bicuspid or in between the tips of the bicuspids. Race-related variation is also noted. For instance, it is frequently found at the tip of bicuspids like the second premolar in Chinese subjects. Whereas in Caucasian subjects, it is found between the premolars and by the canine anteriorly or by the first mandibular molar posteriorly<sup>[7]</sup>. The mental foramen and incisive foramen is a significant landmark during osteotomy procedures. The inferior dental nerve may be seen on medial aspect of the mental foramen and passes far away from it as an anterior loop within the bone that should be considered to prevent injury to mental nerve before performing implant surgery<sup>[8]</sup>. In the present study visibility of mental foramen accounts for about 77% visibility which is similar to that of study conducted by Tejavathi Nagaraj et al. in which total visibility was 99%<sup>[8]</sup>. Visibility of incisive foramen was 25%.

One of the most common complications that may occur following the extraction of mandibular third molars is injury to the inferior alveolar nerve canal (IANC). However, the OPG has been recommended as the primary radiographic investigation of choice in the pre-operative assessment of the mandibular third molar teeth and their surrounding structures<sup>[9]</sup>. OPGs were checked for the appearance of anatomical structures in the mandibular region for implant planning also.

Multiple studies have measured the length of the anterior loop of the inferior alveolar nerve, using anatomical, radiographically and combined methods. These studies show that the panoramic radiographs do not accurately identify the incidence or the extent of the anterior loop. Wei Cheong Ngeow et al. reported that the anterior loop was present in 40.2%<sup>[10]</sup> for all subjects, whereas Arzourman et al.<sup>[11]</sup> and Kuzmanovic et al.<sup>[12]</sup> reported a lower incidence at 12% and 27% respectively. In the present study it showed good visibility in 20% of cases which is similar to previous studies.

The elongated styloid process is an anatomical structure, whose clinical importance is not well understood. Proper clinical and radiographic evaluation can detect an elongated styloid process and calcification of the stylohyoid ligament. It has been reported that 2–28% of the general population show radiographic evidence of mineralization of a portion of the stylohyoid chain. The elongated styloid process may be symptomatic in many cases. Panoramic radiography is the best imaging modality to view the styloid process bilaterally<sup>[13]</sup>. Elongated styloid were present in 19.4% of the panoramic radiographs. Langlais type I elongated styloid and a partial calcification pattern were more common than others. Panoramic radiography is useful for detection of an elongated styloid process and/or ossification of stylohyoid ligaments in patients with or without symptoms and can thus help avoid misinterpretation of the symptoms as tonsillar pain or pain of dental, pharyngeal, or muscular origin<sup>[13]</sup>. In the present study visibility of elongated styloid process was about 25% which is similar to other studies.

## CONCLUSION

Orthopantomographs provided sufficient information of mental foramen and mandibular canal and reliable to visualise pterygomaxillary fissure. But for better visualization, detection of structures like incisive foramen, anterior looping and styloid process for performing surgery, for implant placement in this region or for detecting elongated styloid process in symptomatic patients it may require to be replaced with three-dimensional imaging like cone-beam computed tomography.

## REFERENCES

1. White SC and Paraoh MJ. Oral radiology principles and interpretation. Elsevier Publication, Netherlands; 2014.
2. Robert P, et al. Langland. Diagnostic imaging of jaws. Williams and Wilkins; 1995.
3. Whaites E. Radiography and radiology for dental care professionals. 2<sup>nd</sup> edn. Elsevier Publication, Netherlands; 2009.
4. Juodzbaly G, et al. Anatomy of mandibular vital structures. Part I: Mandibular canal and inferior alveolar neurovascular bundle in relation with dental implantology. J Oral Maxillofac Res. 2010;1:1.
5. Kilic C, et al. The position of the mandibular canal and histologic feature of the inferior alveolar nerve. Clinical Anatomy. 2010;23:34-42.
6. Perschbache S. Interpretation of panoramic radiographs. Australian Dent J. 2012;57:40-45.
7. Agthong S, et al. Anatomical variations of the supraorbital, infraorbital, and mental foramina related to gender and side. J Oral Maxillofac Surg. 2005;63:800-804.
8. Nagaraj T, et al. Visibility of mandibular anatomical landmarks in panoramic radiography: A retrospective study. J Med Radiol Pathol Sur. 2016;2:14-17.

9. Byahatti SM. The relationship of the inferior alveolar nerve canal with the roots of impacted mandibular third molars in a group of the south Indian population. *Indian J Oral Sci.* 2015;6:3.
10. Chen JC, et al. A retrospective comparison of the location and diameter of the inferior alveolar canal at the mental foramen and length of the anterior loop between American and Taiwanese cohorts using CBCT. *Surg Radiol Anat.* 2013;35:11-18.
11. Ngeow WC, et al. A radiographic study on the visualization of the anterior loop in dentate subjects of different age groups. *J Oral Sci.* 2009;51:231-237.
12. Kuzmanovic DV, et al. Anterior loop of the mental nerve: a morphological and radiographic study. *Clin Oral Implants Res.* 2003;14:464-471.
13. Chandramani B, et al. Evaluation of the styloid process on digital panoramic radiographs. *Indian J Radiol Imaging.* 2010;20:261-265.