

## Study of 1<sup>st</sup> Costal Cartilage Calcification on Radiographs in South Indian Population as an Indicator of Age of Human-Beings.

Pushpa MS<sup>1\*</sup>, Roopa Kulkarni<sup>2</sup>, and C Sheshgiri<sup>2</sup>

<sup>1</sup>Department of Anatomy, Bangalore Medical College and Research Institute, Bangalore, Karnataka, India.

<sup>2</sup>Department of Anatomy, MS Ramaiah Medical College, Bangalore, Karnataka, India.

### Research Article

Received: 05/05/2013

Revised: 15/05/2013

Accepted: 11/06/2013

#### \*For Correspondence

No-1810, 7<sup>th</sup> 'A' Main road, 2<sup>nd</sup> stage,  
'E' Block, Rajajinagar, Bangalore-  
560010, Karnataka, India.  
Mobile: +91 9900643266

**Keywords:** Age assessment, First costal cartilage, anthropology, forensic medicine, calcification.

#### ABSTRACT

Progressive calcification of costal cartilages exhibits age and sex distinctive pattern, hence it can be used in the identification of age and sex in living or from skeletal remains. Though the chest radiographs are routinely and extensively examined, costal cartilage calcification has not received a major attention in Radiology literature, more so in relation to age. In the present study on costal cartilage calcification in radiographs, various parameters, have been taken and elaborately analyzed to find the influence of age and sex on patterns of costal cartilage calcification. Some of these parameters have been found very useful, one of which is calcification of first costal cartilages which exhibit a definite pattern in relation to age. Therefore, this study will be useful for Anatomists, experts in forensic medicine and for physical anthropologists to determine the age and sex of an individual from the radiographs and skeletal remains of costal cartilages after the death.

#### INTRODUCTION

The skeleton of the thoracic wall consists of twelve thoracic vertebrae with their intervertebral discs, the twelve pairs of ribs with their costal cartilages and the sternum. There are twelve pairs of ribs that articulate with the vertebral column posteriorly and costal cartilages anteriorly. The costal cartilages are persistent, unossified anterior parts of the cartilaginous models in which the ribs develop. They are flat bars of hyaline cartilage that extend from the anterior ends of the ribs and contribute greatly to thoracic mobility and elasticity. The costal cartilages of upper seven pairs of ribs connect directly to the sternum and they are classified as "true" or "vertebrosternal ribs". The remaining five pairs of ribs are classified as "false ribs"

The costal cartilages are visible on radiographs only when there is calcification within them. Costal cartilages are prone to calcification after adolescence <sup>[1]</sup>. Radiographic examination of costal cartilages is useful and convenient for estimating age and identity of an individual. The individual variation in the appearance of first costal cartilage calcification can be used for the identification of individuals by chest radiographs <sup>[2]</sup>. Calcification of costal cartilages occurs with advancing age, which is observed more frequently in the first costal cartilage.

**Calcification** is the process in which the mineral calcium builds up in soft tissue, causing it to harden.

**Ossification** is the process of bone formation, in which connective tissues, such as cartilage are turned to bone or bone-like tissue. The ossified tissue is invaginated with blood vessels. These blood vessels bring minerals like calcium and deposit it in the ossifying tissue.

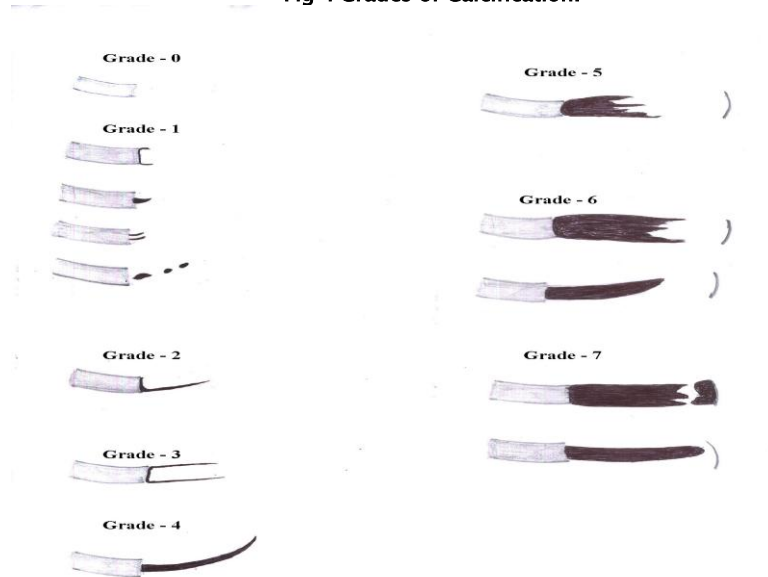
**MATERIAL AND METHODS**

The present study comprised of 600 frontal projection chest radiographs of subjects between 11 and 60 years of age of both sexes without any pathological conditions affecting the bony thorax. For age group, calcification of costal cartilages are graded from 0 to 7 based on McCormick and Stewart (1988) [3], Barchilor V (1996) [4] with some modifications. Patterns of costal cartilage calcification were determined in both sexes as per Verma's methodology<sup>5</sup> with some modifications.

Chest radiographs were taken at a distance of 2 meters for PA view and 1 meter for AP view. Standard radiographic techniques depending on patient's build were used. All the ribs were evaluated for the presence and pattern of costal cartilage calcification. Grading of costal cartilage calcification for estimation of age, the total area of costal cartilage is calculated by measuring breadth between its costal attachment and sternal attachment and length as average length at its costal and sternal ends. The grading are given from 0 to 7 as of reference by McCormick and Stewart (1988)<sup>[3]</sup> and Barchilor (1996) [4] with some modifications. They graded form 0-4 with 0.5 differences between each grade. (Fig. i)

- Grade 0 → No calcification. (Fig. ii)
- Grade 1 → Traces of calcification. (Fig-iii)
- Grade 2 → Calcification along the single margin of the costal cartilage. (Fig-iv)
- Grade 3 → Calcification along both the margins of the costal cartilage. (Fig-v)
- Grade 4 → Prominent central or bifid calcification. (Fig-vi)
- Grade 5 → Mixed - Marginal and central calcification < 50% of calcification. (Fig-vii)
- Grade 6 → Mixed 50-74% of calcification. (Fig-viii)
- Grade 7 → calcification around 75% and above (Fig-ix)

**Fig-i Grades of Calcification.**



**Fig-ii, Grade-0**

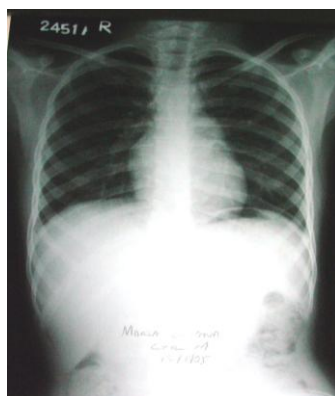


Fig-iii, Grade-1

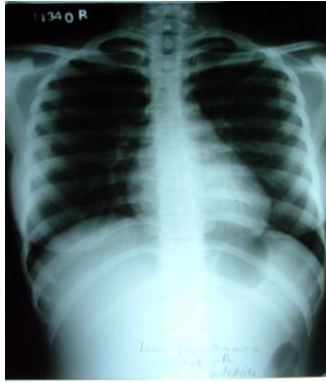

Fig-iv, Grade-2

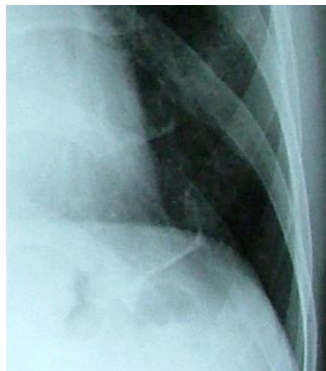


Fig-v, Grade-3

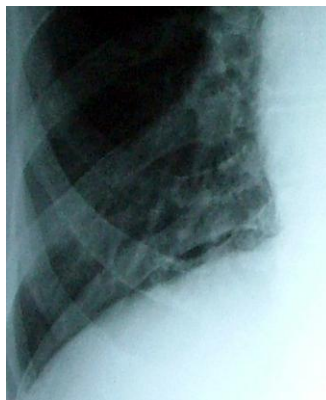

Fig-vi, Grade-4,

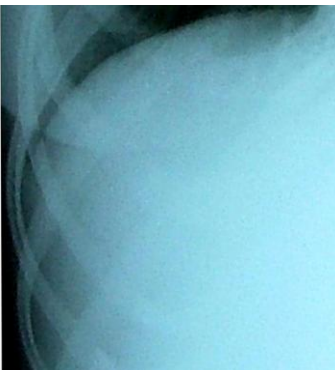

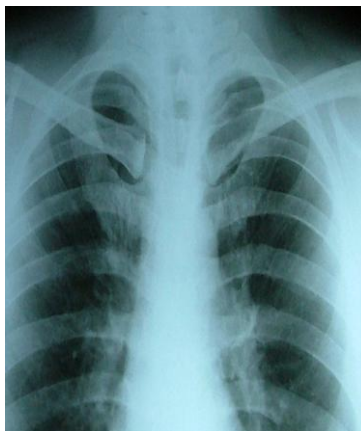
Fig-vii, Grade-5,

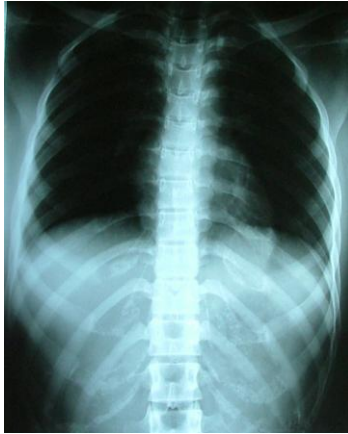

Fig-viii, Grade-6

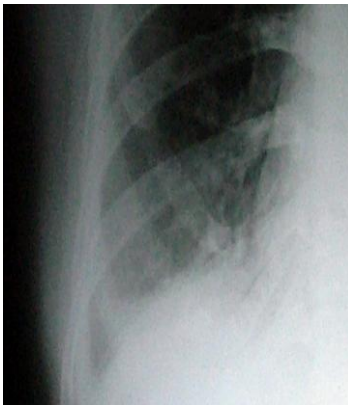

Fig-ix, Grade-7



RESULTS

Table i: Age and Gender distribution of the Study Population

Age in years	Gender		Total
	Male	Female	
11-20	72 (57.14)	54 (42.86)	126
21-30	90 (46.88)	102(53.13)	192
31-40	60 (46.15)	70 (53.85)	130
41-50	38 (40.00)	57 (60.00)	95
51-60	36 (63.16)	21 (36.84)	57
Total	296	304	600

Table ii: Distribution of Grading of Costal Cartilage Calcification in Rib-1 according to Age group

Age Group	Grade	Measurement							Total	
		Grade 0	Grade 1	Grade 2	Grade 3	Grade 4	Grade 5	Grade 6		Grade 7
11-20	Male	60	12	0	0	0	0	0	0	72
		83.30%	16.70%							100%
11-20	Female	37	15	1	0	1	0	0	0	54
		68.50%	27.80%	1.90%		1.90%				100%
21-30	Male	11	39	24	9	0	1	3	3	90
		12.20%	43.30%	26.70%	10.00%		1.10%	3.30%	3.30%	100%
21-30	Female	24	50	17	8	1	1	1	0	102
		23.50%	49.00%	16.70%	7.80%	1.00%	1.00%	1.00%		100%
31-40	Male	9	8	11	11	0	3	12	6	60
		15.00%	13.30%	18.30%	18.30%		5.00%	20.00%	10.00%	100%
31-40	Female	11	24	17	8	0	2	5	3	70
		15.70%	34.30%	24.30%	11.40%		2.90%	7.10%	4.30%	100%
41-50	Male	2	2	2	4	0	2	4	22	38
		5.30%	5.30%	5.30%	10.50%		5.30%	10.50%	57.90%	100%
41-50	Female	11	17	7	7	0	3	8	4	57
		19.30%	29.80%	12.30%	12.30%		5.30%	14.00%	7.00%	100%
51-60	Male	3	1	1	4	0	0	7	20	36
		8.30%	2.80%	2.80%	11.10%			19.40%	55.60%	100%
51-60	Female	10	3	0	0	0	0	2	6	21

Fig- x – Distribution of Grading of Costal Cartilage Calcification in Rib-1 according to Age group among males.

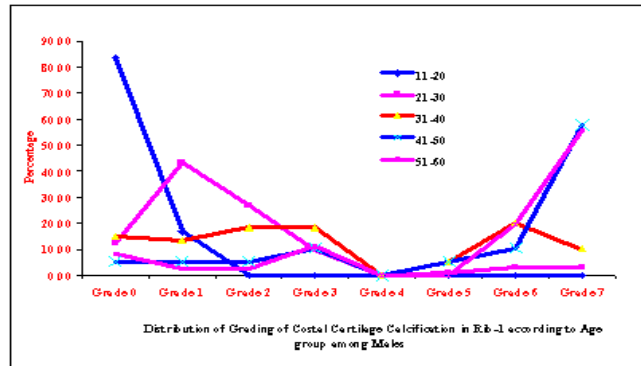
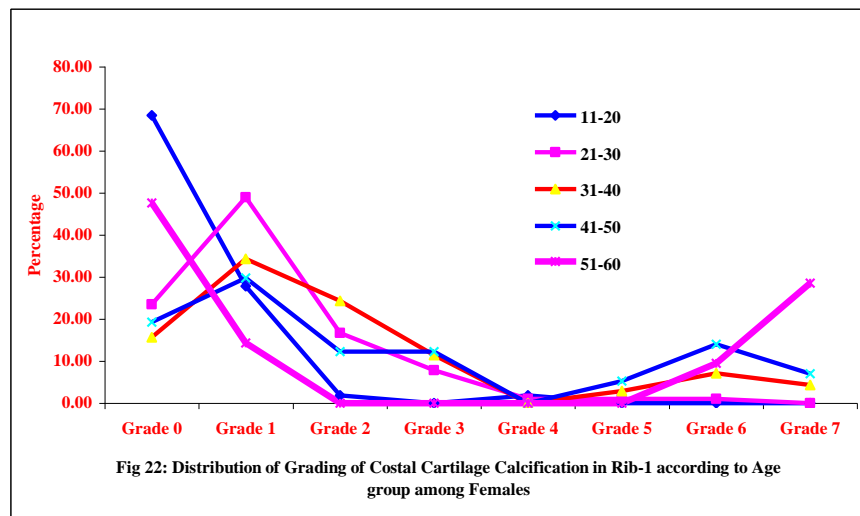


Fig- xi – Distribution of Grading of Costal Cartilage Calcification in Rib-1 according to Age group among females.



DISCUSSION

The present study was undertaken to determine the presence of costal cartilage calcification and influence of age and sex on patterns of costal cartilage calcification. This study can be of value in deciding the age by chest radiographs of living or from the human skeletal remains.

In the present study, the earliest age at which costal cartilage calcification observed was in three males and one female at the age of 15 years. This finding compares well with McCormick who observed earliest occurrence of costal cartilage calcification at 15 years in males. But in his studies, occurrence of costal cartilage calcification in females was at 21 years [3]. Other authors mentioned earliest occurrence of costal cartilage calcification in teens or early twenties irrespective of sexes [2].

Percentage of presence of costal cartilage calcification of first rib is minimum in 11-20 years of age group and increased from 11 years to 50 years in both males and females. This agrees with Charles Teale (1989) who observed an increase from 6% in third decade to 45% in the 9<sup>th</sup> decade [7].

In the present study the presence of costal cartilage calcification in first rib of grade 0 is seen in 85 males and 93 females, of grade 1 is seen in 62 males and 109 females, of grade 02 is seen in 38 males and 42 females, of grade 3 is seen in 28 males and 23

females, of grade 4 is seen 2 females and none in males, of grade 5 is seen in 6 males and 6 females, of grade 6 is seen in 26 males and 16 females, of grade 7 is seen in 51 males and 13 females (Table 1 & 2)

There is an increase in grading of costal cartilage calcification of first rib with increase in age. Among males in 11–20 years age group maximum distribution is in grade 0, in 21–30 years age group in grade 1, in 31–40 years age group in grade 2, 3 and 6, in 41–50 years age group in grade 6 and 7, in 51–60 years age group in grade 7 (Table 2). This agrees with McCormick who observed traces of costal cartilage calcification in all cadavers over the age of 25 years, moderate calcification in 40 years of age, dense calcification in only two individuals below the age of 55 years [3]. Barchilor V (1996) also observed that costal cartilage calcification of the first rib truly manifests the most dramatic morphological changes throughout life [4].

In the present study, the costal cartilage calcification of first rib in grade 1 among females is more when compared to Males. In grade 3, 4 the male shift of higher percentage of calcification is observed. Gradually the percentage of presence of calcification in males is more in grades 5, 6 and 7 when compared to females.

King JB (1939) observed that calcification of costal cartilages is rare before age of twenty and occur with advancing age which is observed more frequently and more extensively in costal cartilage of first rib than others and established that the condition begins at an earlier age in the male sex. He reasoned that costal cartilage calcification is a physiological response of a connective tissue to the strains imposed upon it by muscular action to react towards greater rigidity of anterior chest wall following the assumption of upright posture [6].

Vastine JH et al (1948) have shown similarities in the pattern of costal cartilage calcification in twins and has concluded that calcification of costal cartilage is determined by genetic influence [1].

McCormick (1980) examined radiograph of calcification of costal cartilages from chest plates of 210 cadavers and indicated a roughly linear increase in mineralization with advancing age. It is also observed that there are traces of costal cartilage calcification in all cadavers over the age of 25 years, moderate calcification in 40 years, dense calcification in only two individuals below the age of 55 years [3].

Charles Teale et al (1989) studied 700 chest radiographs, 100 (50 men and 50 women) from each of 3<sup>rd</sup> to 9<sup>th</sup> decades. He examined each radiograph to determine the site and extent of calcific changes in costal cartilages. He observed that prevalence of costal cartilage calcification increased from 6% in the 3<sup>rd</sup> decade to 45% in the 9<sup>th</sup> decade and was commoner in men [7].

Barchilor V (1996) studied the extent of costochondral ossification of the first rib from 78 chest radiographs of 13 healthy male soldiers subjected to a periodic follow-up. Radiographs were taken at a mean interval of 2.9 years over a fifteen-year period. His results showed that calcification of the first costal cartilage start early in adult life and progress at individual rates proceeding from the costal towards the sternal end of the cartilage. The morphological age related changes ranged from formation of small osseous islands in the cartilage to a complete ossification between the first rib and the sternum [4].

## CONCLUSION

This study has been an attempt to examine in detail the presence of costal cartilage calcification and to find out the influence of age on patterns of calcification using various parameters. Calcification of first costal cartilage exhibits a definite pattern in relation to age.

Significant difference in the percentage of costal cartilage calcification in 51 to 60 years age group in females may be due to postmenopausal osteoporosis, a hypothesis that needs to be validated.

## ACKNOWLEDGEMENT

I thank Dr. R.N.Kulkarni, Professor & Head of the Department of Anatomy, M.S.U., International Medical School, M.S.Ramaiah campus, Bangalore, the faculty in the Department of Radiology M. S. Ramaiah medical college and all the staff of anatomy, M.S.Ramaiah Medical college, Bangalore for the timely help and valuable suggestions during the study. I also thank the statistician and all my family members for the help and moral support given to me during this work.

## REFERENCES

1. Vastine JH et al. Genetic influence of osseous development with particular reference to the deposition of calcium in the costal cartilages. American J Roentgenol. 1948;59 (2): 213–221.

2. Grainger RG et al. 1992, Diagnostic Radiology: An Anglo-American Textbook of Imaging 2<sup>nd</sup> ed., Churchill Livingstone U. K., pp 165-166.
3. McCormick WF, Stewart JH. Age related changes in human plastron: Roentgenographic and A morphologic study. J Forensic Sci. 1988;33: 100-120.
4. Barchilor V. et al. Factors affecting the rate and pattern of the first costal cartilage ossification: Am J Forensic Med Pathol. 1966;17 (3): 239-247.
5. Verma GL. Sex determination by costal cartilage calcification. Indian J Radiol. 1980; 34: 22-25.
6. King JB. Calcification of the costal cartilages. British J Radiol. 1939;XII (133):2-12.
7. Charles Teale et al. Calcification on chest radiographs: The Association with age. Oxford Journals - Medicine. Age and Ageing. 1989; 18(5):333-336.