

# Retrieval of Reproductive Complications by Exogenous Melatonin Treatment in Streptozotocin Induced Diabetic Rat Model

Younis Ahmad Hajam, Seema Rai\*, Swati Shree, Muddasir Basheer and Hindole Ghosh

Department of Zoology, Guru Ghasidas Vishwavidyalaya (Central University), Koni, Bilaspur, Chhattisgarh, India

## Research Article

Received date: 30/06/2017

Accepted date: 29/11/2017

Published date: 30/11/2017

### \*For Correspondence

Seema Rai, Department of Zoology,  
Guru Ghasidas Vishwavidyalaya (Central  
University), Koni, Bilaspur, Chhattisgarh,  
India. Tel: +91-7752-260471.

**E-mail:** raiseema\_pk@rediffmail.com

**Keywords:** Melatonin, Diabetic rat model,  
Reproductive complications, Streptozotocin

### ABSTRACT

This study was aimed to evaluate the altered histoarchitecture and biochemical changes in Testis, Epididymis and Seminal vesicle of male albino rats treated with streptozotocin. Also, another objective was to evaluate the possible protective role of using exogenous melatonin in combination with streptozotocin. After histological and biochemical analysis, it was concluded that the exogenous melatonin may be used with other antioxidants to enhance and modulate the functions of antioxidative system and also to overcome cellular damages during diabetes

## INTRODUCTION

The modernization and changing life style makes our body prone to several diseases. They affect physiological processes of the body sooner or later, focusing on male reproduction leading to decrement in reproductive performance. The worldwide survey reported that the diabetes affecting nearly 10% of the population<sup>[1]</sup> and is the eighth leading cause of death (after heart disease and cancer) in many developed countries. It is characterized by hyperglycemia, hypertriglyceridemia and hypercholesterolemia resulting from defects in insulin secretion or reduced sensitivity of the tissue to insulin (insulin resistance) and/or combination of both<sup>[2]</sup>. It has a detrimental effect on sexual function, especially in male individuals. Alterations in male reproductive functions develop in diabetes as it reduces the endocrine control of spermatogenesis by imposing an oxidative stress that results in decreased libido, delayed sexual maturation, and infertility with poor semen quality. Prospective studies have shown that low testosterone levels predict the development of diabetes in men<sup>[3]</sup>. Although the exact mode of regulation of male free testosterone and fasting insulin levels in diabetic men independent of age, obesity, and body fat distribution. Diabetes reduces sperm count, serum testosterone and impairment of spermatogenesis, seminal fluid volume, erectile dysfunction and loss of sexual ability.

Streptozotocin, an antibiotic and anticancer agent, most prominent diabetogenic agent in diabetes research due to its cytotoxicity in pancreatic  $\beta$ -cells. It is a potent growth inhibitor and alkylating agent, used for the treatment of colorectal, pancreatic, adrenocortical and gastrointestinal cancers in single as well as in combination with other antineoplastic agents<sup>[4]</sup>. The selective toxicity of STZ to  $\beta$ -cells occurs because of its preferential accumulation in  $\beta$ -cells through uptake via GLUT-2 glucose transporter. Earlier studies suggest that chemotherapeutic treatment of different malignancies using STZ results in the formation of antibodies<sup>[5]</sup>, which may in turn, starts the destruction of insulin producing  $\beta$ -cells and finally leads to deficiency of insulin<sup>[6]</sup>. Therefore, it leads to the hyperglycemia level in the body. The surplus glucose gets auto-oxidized and becomes the origin of free radical production. Some amount of excess glucose causes non-enzymatic glycation of proteins like hemoglobin converts them into glycosylated hemoglobin.

Melatonin is a natural compound found in humans, animals, and microbes, animals and plants<sup>[7]</sup>. It is synthesized in the pineal gland and also from other extra-pineal sites (such as retina, intestine, bone marrow cells and skin)<sup>[8]</sup>. The circulating levels of the hormone melatonin vary in a daily cycle. It has a powerful anti-oxidant effect and reduces oxidative stress, because of self-oxyradical scavenger and stimulates the endogenous antioxidant systems; superoxide, glutathione oxidase, glutathione S transferase (GST) and total thiol in blood and in liver<sup>[9]</sup>. As melatonin-binding sites have been detected in the reproductive systems of different species, it seems reasonable to assume that melatonin exerts its actions through a direct interaction with

the steroidogenic cells of the reproductive organs. The antioxidant function of melatonin has been associated with its capacity to scavenge reactive oxygen/nitrogen species (ROS/RNS). In addition, melatonin reduces free radical levels by stimulating the activities of antioxidative enzymes. It has been studied exogenous melatonin treatment restores the oxidative stress and hormonal level in PCOS female albino rats <sup>[10]</sup> and also reported that it reduces streptozotocin induced hepatorenal impediments viz lipid peroxidation rate, liver and kidney function tests <sup>[11]</sup>. Melatonin Present study, aimed to evaluate the altered histoarchitecture and biochemical changes in Testis, Epididymis and Seminal vesicle of male albino rats treated with streptozotocin. Also, another objective was to evaluate the possible protective role of using exogenous melatonin in combination with streptozotocin.

## MATERIALS AND METHODS

### Animal and Experimental Design

**Table 1.** Experimental design.

Groups	Dosage	No. of animals
Control	0.5 ml (0.1M) citrate buffer	6
Streptozotocin (STZ)	15 mg/kg	6
STZ+MEL	15 mg+1 mg/kg	6
Melatonin (MEL)	1 mg/kg	6
Glibenclamide (GB)	0.6 mg/kg	6
STZ+GB	15 mg/kg+0.6 mg/kg	6

Streptozotocin (STZ) was dissolved in 0.1M citrate buffer (pH 7.4) at dose of 15 mg/kg and administered intraperitoneally for six consecutive days. Blood glucose level of the animals was monitored using Glucometer (ACCU CHECK) after 72 hours of streptozotocin (STZ) treatment. Rats with blood glucose level exceeding higher than 250 mg/dl till 6th day were confirmed as diabetic model 30 days (**Table 1**).

### Histological Studies

After the completion of experiment, rats were anesthetized by give them Diethyl ether and then sacrificed. Testis and male accessory organs (seminal vesicle and epididymis) were dissected out, cleaned and weighed. Tissues were fixed in Bouin's fixative for 24 hours and were processed for biochemical analysis. They were processed through the various steps of dehydration and clearance, and then embedded in paraffin wax. Tissue sections of 5 µm thick were cut using rotary microtome (Leica RM 2125RT5) and then staining was done by double staining method. Histomicrograph of sections were groped in Trinocular research microscope under 400x magnifications.

### Biochemical Analysis

**Determination of total protein content:** Total protein was estimated following the method of <sup>[12]</sup> with some modifications. Tissue was homogenized in Na<sub>2</sub>CO<sub>3</sub> to make 10% solution. Bovine serum albumin was used to make standard curve and absorbance was taken at 635 nm.

**Lipid Peroxidation (LPO) assay:** TBARS assay was performed to estimate the lipid peroxidation (LPO) following the modified method of <sup>[13]</sup>. Tissues were homogenized in Tris-HCL (20 Mm) Absorbance was take absorbance at 535 nm in Perkin Elmer Spectrophotometer (Lambda 25, serial No. 501812090210). The rate of LPO was expressed as nanomolar of TBARS per gram fresh tissue weight using a molar extinction co-efficient of 1.56 × 10<sup>5</sup> M/cm.

**Determination of reduced glutathione (GSH):** The thiol content was measured by using the modified method of Sedlak and Lindsay <sup>[14]</sup>. Tissue homogenate was prepared in 0.025M sucrose. Absorbance at 412 nm (Perkin Elmer Spectrophotometer, Lambda 25, serial no. 501812090210). The molar extinction coefficient of 13,100 was used to calculate GSH content.

**Superoxide Dismutase (SOD) activity:** Superoxide dismutase (SOD) activity in tissues was assessed by using the modified method of Kakkar et al., <sup>[15]</sup>. Tissue homogenate was prepared in 0.25M sucrose and absorbance was taken at 560 nm using Perkin Elmer Spectrophotometer (Lambda 25, serial no. 501812090210).

**Catalase (CAT) activity:** The Catalase activity was determined by modified method of Beers and Sizer <sup>[16]</sup>. Tissue homogenate was prepared in phosphate buffer. Absorbance was taken at 240 nm for 3 minutes in Perkin Elmer Spectrophotometer (Lambda 25, serial no. 501812090210).

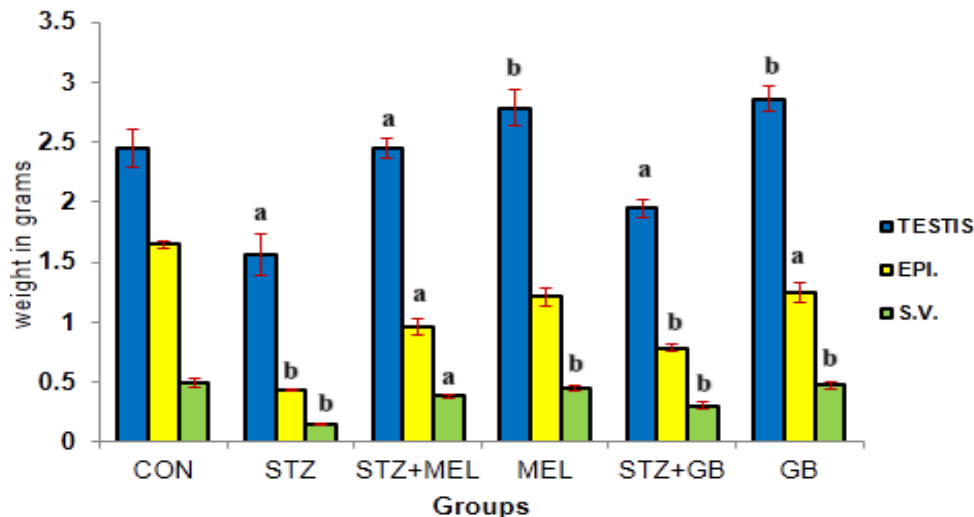
### Statistical Analysis

Statistical analysis was performed using One-way ANOVA followed by Student's t-test with the SPSS 16.0 statistical software (SPSS, Chicago, IL, USA). A probability value p<0.05 or p<0.01 was considered to be statistically significant.

## RESULTS

### Organ Weight

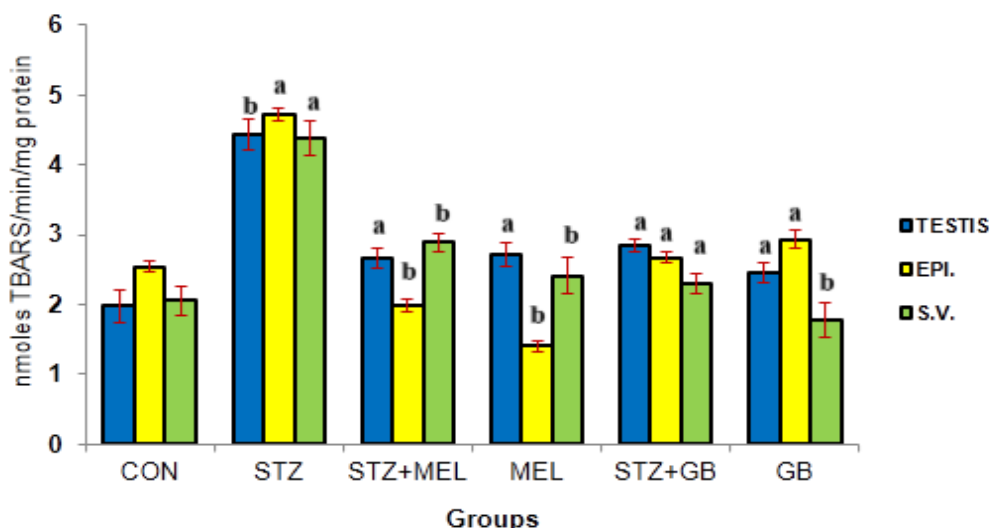
Diabetic rats showed significant decrease in organ weight, whereas melatonin administration to the diabetic rats increased the organ weight to the level of control. The melatonin and glibenclamide alone were shown to maintain the similar organ weight as that of control groups (**Figure 1**).



**Figure 1.** Comparative effect of melatonin (MEL) and glibenclamide (GB) on weight of testis, epididymis and seminal vesicle respectively of streptozotocin induced diabetic rats. Histogram represents mean  $\pm$  SE; N=6; showing level of significance as a= $p \leq 0.05$  and b= $p \leq 0.01$  for CON vs. STZ; STZ vs. STZ+MEL; STZ vs. MEL; STZ vs. STZ+GB and STZ vs. GB respectively.

### LPO Assay (Oxidative Stress Marker)

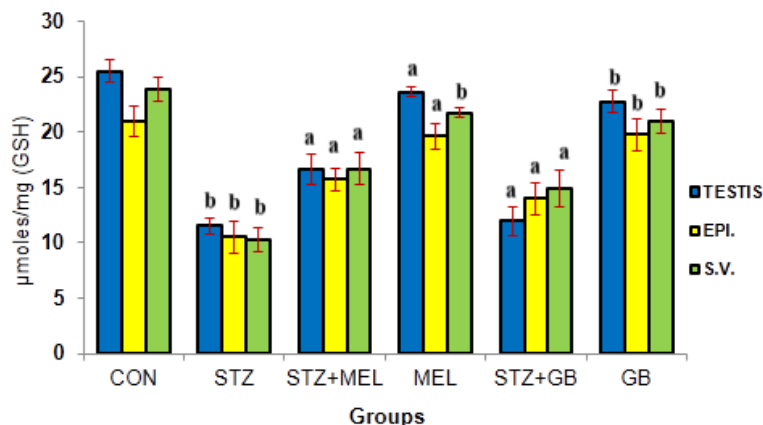
The free radical production was noted significantly higher in tissues of testis and accessory sex organs (epididymis and seminal vesicle) of streptozotocin induced diabetic control rats. As STZ induced diabetic rats given injection of melatonin and glibenclamide intraperitoneally, it showed significant decrease in TBARS level of tissues. Melatonin and glibenclamide alone showed significant regulation of free radical generation (**Figure 2**).



**Figure 2.** Comparative effect of melatonin (MEL) and glibenclamide (GB) on lipid peroxidation (LPO) in testis, epididymis and seminal vesicle of streptozotocin induced diabetic rats. Histogram represent mean  $\pm$  SE; N=6; showing level of significance as a= $p \leq 0.05$  and b= $p \leq 0.01$  for CON vs. STZ; STZ vs. STZ+MEL; STZ vs. MEL; STZ vs. STZ+GB and STZ vs. GB respectively.

### Reduced Glutathione (GSH)

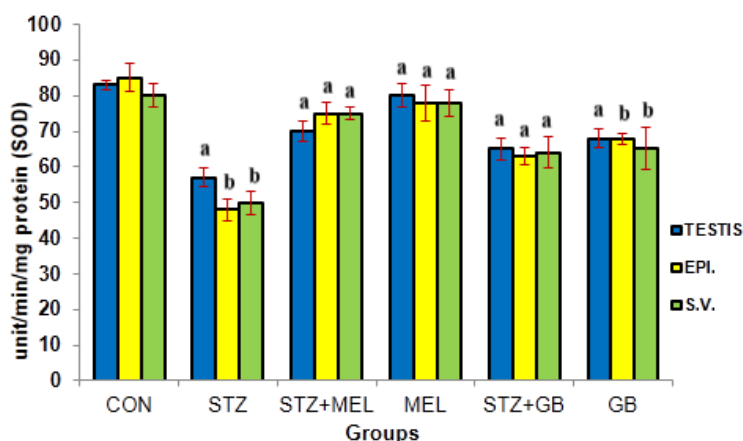
The GSH level was noted decreased significantly in streptozotocin diabetic rats. Melatonin supplemented to streptozotocin diabetic rats showed gradual increase in thiol content in the cells of given organs. The results were compared with standard anti-diabetic component (Glibenclamide) treated group (**Figure 3**).



**Figure 3.** Comparative effect of melatonin (MEL) and glibenclamide (GB) on glutathione reduced (GSH) in testis, epididymis and seminal vesicle of streptozotocin induced diabetic rats. Histogram represent mean ± SE; N=6; showing level of significance as a=p ≤ 0.05 and b=p ≤ 0.01 for CON vs. STZ; STZ vs. STZ+MEL; STZ vs. MEL; STZ vs. STZ+GB and STZ vs. GB respectively.

### Superoxide Dismutase Activity

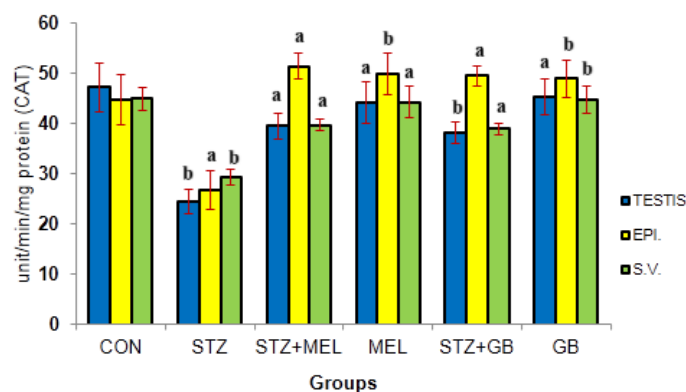
Significant decrease in SOD activity was observed in streptozotocin induced diabetic rats in tissues, whereas exogenous melatonin treatment to the diabetic rats showed increment in antioxidant enzyme activity. SOD activity showed comparably increase like the glibenclamide and control rats (**Figure 4**).



**Figure 4.** Comparative effect of melatonin (MEL) and glibenclamide (GB) on superoxide dismutase activity (SOD) of given organs of streptozotocin induced diabetic rats. Histogram represent mean ± SE; N=6; showing level of significance as a=p ≤ 0.05 and b=p ≤ 0.01 for CON vs. STZ; STZ vs. STZ+MEL; STZ vs. MEL; STZ vs. STZ+GB and STZ vs. GB respectively.

### Catalase (CAT) Activity

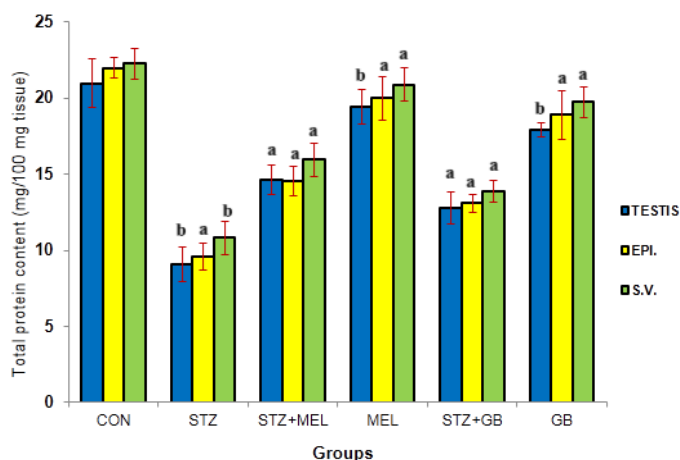
Streptozotocin (STZ) induced diabetic rat model showed significant decrease in catalase (CAT) activity (enzyme which cleaves the H<sub>2</sub>O<sub>2</sub> into water and molecular oxygen) in testis, epididymis and seminal vesicle of streptozotocin (STZ) induced diabetic model showed significant increase in catalase activity and compared to the control and glibenclamide (**Figure 5**).



**Figure 5.** Comparative effect of melatonin (MEL) and glibenclamide (GB) on Catalase activity (CAT) in testicular cells, epididymis and seminal vesicle of streptozotocin induced diabetic rats. Histogram represent mean ± SE; N=6; showing level of significance as a=p ≤ 0.05 and b=p ≤ 0.01 for CON vs. STZ; STZ vs. STZ+MEL; STZ vs. MEL; STZ vs. STZ+GB and STZ vs. GB respectively.

**Total Protein Content Estimation**

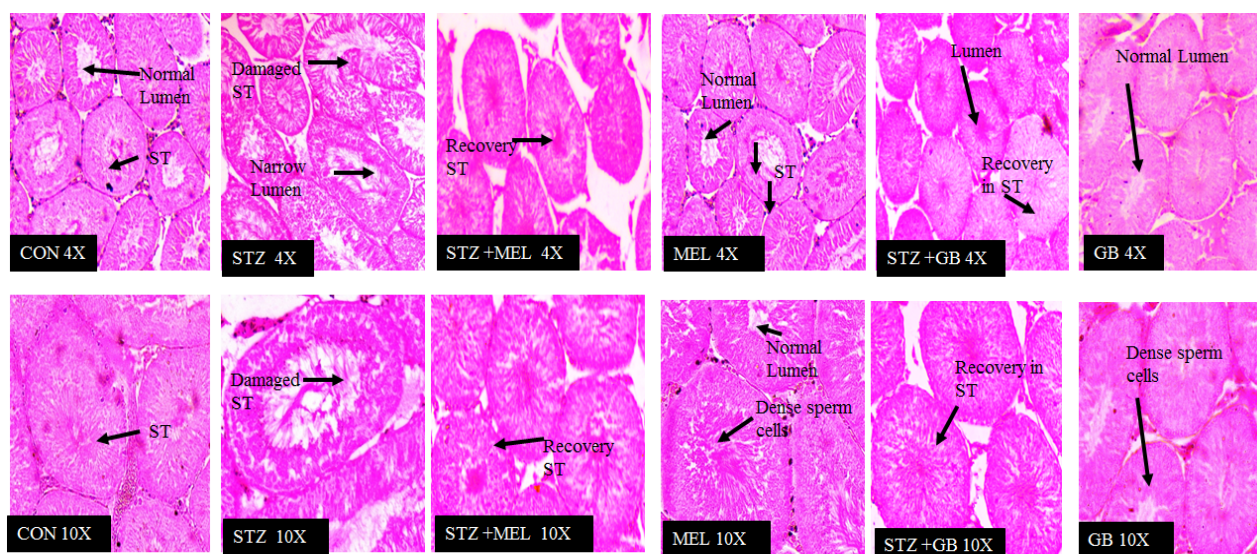
Total protein content was noted significantly reduced in given organs of streptozotocin (STZ) induced diabetic rats. While as significant increase in total protein content of tissues was observed in STZ induced diabetic rats treated with melatonin and glibenclamide by intraperitoneally injection. The results were compared with standard anti-diabetic molecule (Glibenclamide) treated group (Figure 6).



**Figure 6.** Comparative effect of melatonin (MEL) and glibenclamide (GB) on estimation of total protein in testis, epididymis and seminal vesicle of streptozotocin induced diabetic rats. Histogram represent mean ± SE; N=6; showing level of significance as a=p ≤ 0.05 and b=p ≤ 0.01 for CON vs. STZ; STZ vs. STZ+MEL; STZ vs. MEL; STZ vs. STZ+GB and STZ vs. GB respectively.

**Histomicrograph of Testis**

The histological observations showing decrease in lumen of seminiferous tubules and shrinkage during diabetic condition while as melatonin treatment recovered the shrinkage and increased population of spermatogenic cells (Figure 7).

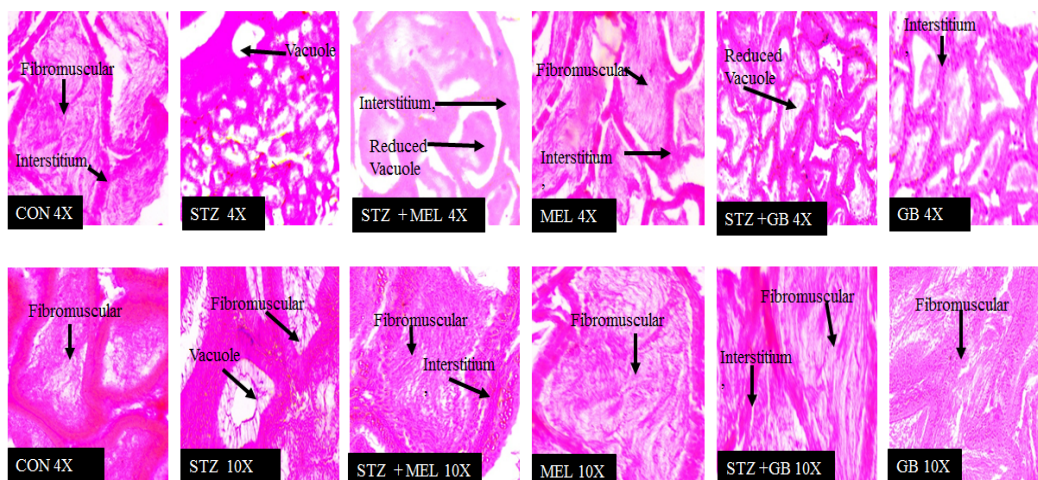


**Figure 7.** Histophotomicrographs represents alterations in the tissue of the testis. Control group of rats showed normal seminiferous tubules (ST), well-populated sperm cells and normal lumen. STZ induced rats showed decreased size and abnormal shape of seminiferous tubules. STZ+MEL group recovered the lumen size, increased the sperm population and restored the cellular deformities. MEL and GB treated rats does not showed any cellular abnormality, but has regulated the cellularity of testis.

**Histomicrograph of Epididymis**

Histological architecture of epididymis demonstrated vacuole formation, fibromuscular degeneration and also interstitium decreased in STZ induced diabetic rats. These alterations might be affecting sperm maturation and motility. The important storage house of sperms is epididymis; any cellular aberration in epididymis may leads to infertility. Melatonin treatment recovers the cellular anomalies comparable to control. However, glibenclamide also showed recovery in cellular damages. Melatonin and glibenclamide alone regulated the cellularity of epididymis (Figure 8).

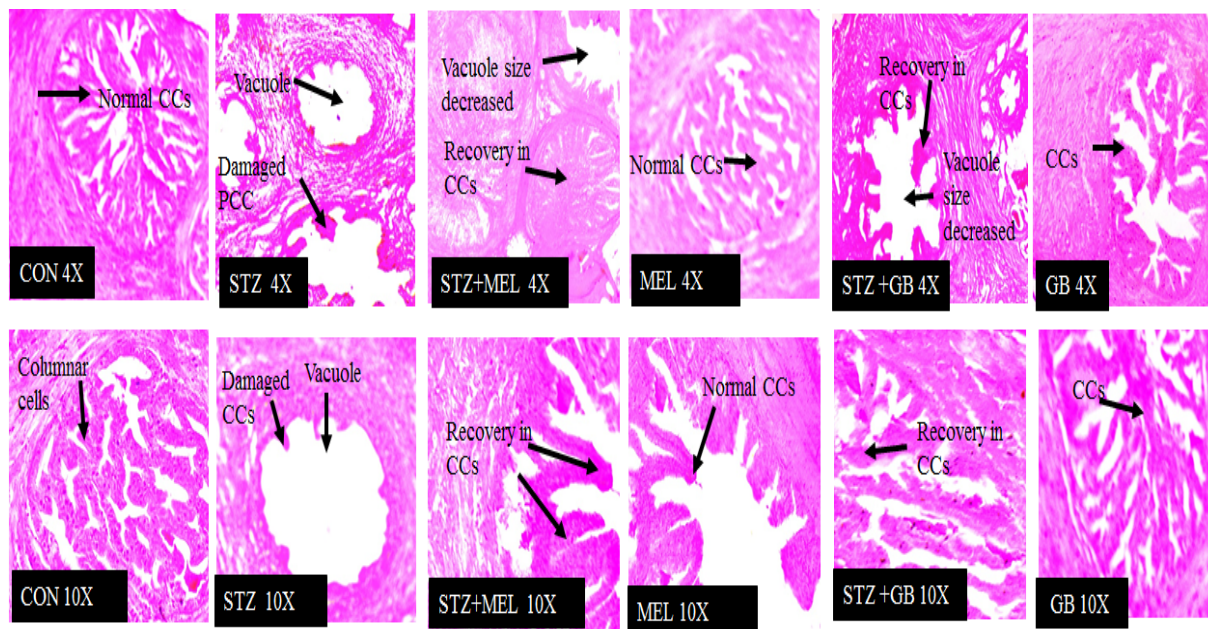




**Figure 8.** Histophotomicrographs represent alterations in the tissue of the epididymis. Control group of rats does not show any cellular damage, while as STZ treated rats showed vacuole formation, decreased fibromuscular tissue and damage in interstitium in epididymis. STZ+MEL recovered the cellular alterations like decreased vacuole size, normalized fibromuscular tissue and recovery in interstitium. STZ+GB treated animals showed recovery in these cellular changes. MEL and GB treated groups does not show any damages.

### Histomicrograph of Seminal Vesicle

Histological observations of seminal vesicle were noted reduced number of columnar cells which in turn inhibits the secretion of fluids. However, melatonin administration recovers the population of columnar cells which was comparable to control groups. Glibenclamide given to diabetic rats showed recovery in the columnar cell damages, but significant restoration was observed in melatonin treated diabetic rats. Melatonin and glibenclamide alone maintained the structural and functional modulation of seminal vesicle (**Figure 9**).



**Figure 9.** Histophotomicrographs represent alterations in the tissue of the seminal vesicle. Control group showing normal pseudostratified large columnar epithelial cell, typical basal cells in the epithelium and no vacuole formation, degenerated columnar cells (CCs), STZ+MEL and STZ+GB group showed decrease in vacuole size and recovery in columnar cells (CCs). However, significant recovery was observed in melatonin treated group. Melatonin and glibenclamide regulated the cellular architecture of seminal vesicles.

## DISCUSSION

Diabetes mellitus (DM) affects 8.3% of the world population and approximately 5.1 million people aged between 20 and 79 years died from diabetes in 2014 (IDF, 2014). The high mortality and negative impact of diabetes on life quality are due to the progressive impairment of multiple organ systems, caused mainly by hyperglycemia and oxidative stress <sup>[17]</sup>. STZ is a  $\beta$ -cell toxin, which is used widely as a diabetogenic molecule to induce diabetes in experimental animals. It induces free radicals and enhances

oxidative stress, which is responsible for the manifestations of different toxicities. STZ induces hyperglycemia by damaging the insulin secreting  $\beta$ -cells. Mechanisms that contribute to the formation of free radicals in diabetes may include not only increased non-enzymatic and auto-oxidative glycosylation but also metabolic stress resulting from changes in energy metabolism, levels of inflammatory mediators, and the status of antioxidant defense <sup>[18]</sup>. Melatonin is considered to be highly lipophilic and hydrophilic in nature. This facilitates its transport through all biological membranes to enter the cells and their subcellular compartments. As a result of this, its administration via any route shows a rapid rise in melatonin concentration, which may allow it to reduce oxidative damages in both lipid and aqueous environment of cell. This overshadows other anti-oxidants which penetrates the cells slowly.

In the present study, gravimetric analysis showed tissue specific variation in different reproductive organs, where epididymis and seminal vesicle were found more affected during diabetic condition than testis this signifies that there might be any alteration in cellular architecture causing atrophy leading to decrease in organ weight. This might be one of the strong reasons behind the epididymis and seminal vesicle dysfunction during diabetic induced male infertility as healthy, as epididymis promotes sperm maturation and storage. It has been confirmed that STZ induced diabetes leads to decrease in the weight of tissues in the genitourinary tract of male rats <sup>[19]</sup>. Melatonin as an antiapoptotic molecule might be prevents the cellular death, thus exogenous administration of melatonin recovered the loss of organ weight.

In the present study, TBARS level was determined as an oxidative marker to analyze the stress level in animal model. A significant elevation in TBARS level was observed in STZ induced diabetic rats in comparison to control rats. This signifies a prominent free radical production in STZ induced diabetic rats. Reduction in ROS production by administration of melatonin to diabetic rats showed that melatonin acts as a free radical scavenger. Results were confirmed melatonin per see treatment to the rats which does not showed any alteration in free radical production like that the anti-diabetic drug (Glibenclamide). The result of present study was coinciding with the previous findings of Lena and Subramanian who reported that melatonin a potent antioxidant and a free radical scavenger. They concluded that melatonin could control the oxidative abuse by (i) directly scavenging a variety of radicals and ROS, (ii) inducing antioxidative enzymes which reduce the steady state levels of ROS, (iii) inhibiting nitric oxide synthase, which generates nitric oxide, and (iv) stabilizing cell membranes that aid them in reducing oxidative damage. Similar results by Gutierrez-Cuesta et al., <sup>[20]</sup> have been reported that melatonin improved prosurvival signals and reduced prodeath signals. It has been suggested that melatonin may potentially attenuate testicular damage by improving histopathological changes and reducing germ cell apoptosis in hyperglycemic mice <sup>[21]</sup>. The lipids in spermatozoa are the main substrates for peroxidation, and showed that excess amounts of ROS and free radicals have adverse effects on sperm motility and fertility <sup>[22]</sup>. Moreover, the lipid content of cell membranes seems to be disrupted by diabetes as proved by increased non-enzymatic glycation, lipid peroxidation and cholesterol phospholipid ratio Watala and Winocour.

Hyperglycemia leads to the increased production of free radical intermediates via at least four different routes: increased glycolysis; intracellular activation of the sorbitol (polyol) pathway; auto-oxidation of glucose and non-enzymatic protein glycation Ahmed (2005). To control the flux of ROS, aerobic cells have developed an antioxidant defense system, which includes enzymatic and non-enzymatic components <sup>[23]</sup>. The antioxidant system consists of low molecular weight antioxidant molecules and various antioxidant enzymes <sup>[24]</sup>. Glutathione (GSH), the most prevalent low molecular weight antioxidant peptide, superoxide dismutase and catalase activity.

Glutathione reduced (GSH), superoxide dismutase (SOD), Catalase (CAT), Glutathione peroxidase (GPx), GSH cycle (includes GPx, G6PDH, GR, NADPH and ATP as well), all enzymatic and non-enzymatic systems gets weakened during the diabetic conditions. STZ induces OFR induced lipid peroxidation and breaking of DNA strands in reproductive organs. Changes in SOD and catalase activity, glutathione and vitamin-E levels have been reported Oberley and Oberley <sup>[25]</sup>. During diabetic state SOD activity decreases significantly in testis, epididymis and seminal vesicle in both rats and mice. In this study, decrease in level of GSH, SOD and catalase reveals weakening of antioxidative defense mechanism during diabetes. While administration of melatonin showed a recovery as in comparison of control. This put forward that melatonin treatment could improve the testicular damages at both cellular and biochemical level in diabetic rats partly by restoring SOD activity and inhibiting oxidative stress. As a result, ROS production is decreased and testicular damages in diabetic rats is ameliorated. There is evidence that, streptozotocin- induced diabetes releases free radicals <sup>[26]</sup>. As glutathione is closely linked to glucose metabolism via NADPH of hexose monophosphate shunt, it is logical that free radical metabolism is altered in diabetes.

The present study indicated a prominent decrement in total protein content of the organs. This decrease in protein content might be due to membrane damages leads to exudation of proteins out from the cells and might be reason for organ dysfunction and irregularity in protein metabolism. Till date, least reports are available regarding the protein quantification in testes, epididymis and seminal vesicle. Therefore, decrement in total protein content reduces the reproductive ability during diabetic condition, which might be one of the causes of infertility.

Histological observation study showed atrophy in seminiferous tubules degeneration in germinal cells, disorganization in germinal cells, interstitial oedema and capillary congestion and decrease in spermatogenic cells. These changes were also reported by the previous findings lead to the failure of sperm formation and failure consistently <sup>[27]</sup>. Earlier studies confirmed similar

alterations in the morphology of the testis [28,29]. Spermatogonium mother cells are germ cells showed apoptosis, reduction of spermatogenic cell series [30] which results in diverse histocellular aberrations such as marginal distortion, decreased number of sperms, and shrinkage in volume, which indicated that sperm population significantly reduced during diabetic condition. However, melatonin administration to STZ induced rats restored the aberrant changes in testicular function. Impairments in the epididymis might lead to improper sperm motility and reduced fertility in STZ-diabetic rats. Necrosis in the cellular architecture may lead to formation of vacuoles, vascular congestion, macrophage infiltration and accumulation of edematous fluid in the interstitial space [31]. It is reported in previous studies that during diabetic condition secretory cells (pseudostratified columnar cells) of seminal vesicle decreased in number and vacuole formation occurs due to increased cellular damages. These cellular damages might have occurred because of free radical generated abnormal cellular death [32-38]. However, melatonin administered to diabetic rats recovered the cellular damages. Epididymis cellular architecture during diabetic condition showing decreased size of interstitium and reduced fibro muscular tissue which might be affecting sperm maturation and may lead to male infertility/sterility. This was supported by the histological observation of [31]. Melatonin treatment showed restoration in cellular alterations towards the control. Melatonin and glibenclamide regulated the cellular and functional status of epididymis.

## **CONCLUSION**

Melatonin has various reparative biological functions such as antioxidative, immunomodulation, oncostatic, antiageing and anti-inflammatory roles. These functions compel the scientific community to explore its protective roles. In the present study rate of lipid peroxidation were observed high (in terms of TBARS level), antioxidative system (GSH, SOD and CAT) showed decrement in diabetic condition induced by STZ, melatonin showed very interesting results in way by modulating antioxidative defense diabetic rats significantly upregulating the antioxidative system. Histological photomicrography showed restoration in cellular damages in testes, epididymis and seminal vesicle induced by STZ induction. Therefore, exogenous melatonin may be used with other antioxidants to enhance and modulates the functions of antioxidative system and also to overcome cellular damages during diabetes. Further, studies are needed to explore its action mechanism at non-receptor as well as receptor level which may prove helpful to medical science in the field of male infertility induced during diabetic condition.

## **DECLARATION OF INTEREST**

Authors have no conflict of interest.

## **ACKNOWLEDGEMENTS**

Authors are highly grateful to the Department of Zoology, Guru Ghasidas Vishwavidyalaya (Central University) for providing available research facilities. Authors are also thankful to Dr. SK Verma (Department of Zoology, GGV) for lending his help during microscopy.

## **REFERENCES**

1. Kim JD, et al. Anti-diabetic activity of SMK001, a poly herbal formula in streptozotocin induced diabetic rats: therapeutic study. *Biol Pharm Bull* 2006;29:477-482.
2. Mishra A, et al. Antihyperglycaemic activity of six edible plants in validated animal models of diabetes mellitus. *Indian J Sci Technol* 2009;2:80-86.
3. Laaksonen DE, et al. Testosterone and sex hormone-binding globulin predict the metabolic syndrome and diabetes in middle-aged men. *Diabetes Care* 2004;27:1036-1041.
4. Strosberg JR and Kvols LK. A review of the current clinical trials for gastroenteropancreatic neuroendocrine tumours. *Expert Opin Investig Drugs* 2008;16:219-24.
5. Akbarzadeh A, et al. Induction of diabetes by streptozotocin in rats. *Indian J Clin Biochem* 2007;22:60-64.
6. Szkudelski T. The mechanism of alloxan and streptozotocin action in B cells of the rat pancreas. *Physiol Res* 2001;50:537-46.
7. Basheer M and Rai S. Melatonin vs. phytemelatonin: Therapeutic uses with special reference to polycystic ovarian syndrome (PCOS). *Cogent Biol.* 2016;21136257.
8. Ikegami T, et al. Diurnal expressions of four subtypes of melatonin receptor genes in the optic tectum and retina of goldfish. *Comp Biochem Physiol A Mol Integr Physiol* 2009;152:219-224.
9. Vani M, et al. Glutathione-S-transferase, superoxide dismutase, xanthine oxidase, catalase, glutathione peroxidase and lipid peroxidation in the liver of exercised rats. *Biochem Res Int* 1989;21:17-26.
10. Rai S, et al. Melatonin Attenuates Free Radical Load and Reverses Histologic Architect and Hormone Profile Alteration in Female Rat: An In vivo Study of Pathogenesis of Letrozole Induced Poly Cystic Ovary. *J Clin Cell Immunol* 2015;6:1-8.



11. Rai S, et al. Biochemical and Histopathological Inflections in Hepato-renal Tissues of Streptozotocin (STZ) Induced Diabetic Male Rats: Impact of Exogenous Melatonin Administration. *J Clin Res Bioeth* 2016;7:1-11.
12. Lowry OH, et al. Protein measurement with the Folin phenol reagent. *J Biol Chem* 1951;193:265-275.
13. Ohkawa H, et al. Assay for lipid peroxides in animal tissues by thiobarbituric acid reaction. *Anal Biochem* 1979;95:351-358.
14. Sedlak J and Lindsay RH. Estimation of total, protein-bound, and nonprotein sulfhydryl groups in tissue with Ellman's reagent. *Anal Biochem* 1968;25:192-205.
15. Kakkar P, et al. A modified spectrophotometric assay of superoxide dismutase. *Indian J Biochem Biophys* 1952;21:192-205.
16. Beers RF and Sizer IW. A spectrophotometric method for measuring the breakdown of hydrogen peroxide by catalase. *J Biol Chem* 1952;195:133-140.
17. Wautier MP, et al. Activation of NADPH oxidase by AGE links oxidant stress to altered gene expression via RAGE. *Am J Physiol Endocrinol Metab* 2001;280:685-694.
18. Griesmacher A, et al. Enhanced serum levels of thiobarbituric acid reactive substances in diabetes mellitus. *Am J Med Sci* 1995;98:469-475.
19. Soudamani S, et al. Experimental diabetes has adverse effects on the differentiation of ventral prostate during sexual maturation of rats. *Anat Rec A Discov Mol Cell Evol Biol* 2005;287:1281-1289.
20. Gutierrez-Cuesta J, et al. Evaluation of potential pro-survival pathways regulated by melatonin in a murine senescence model. *J Pineal Res* 2008;45:497-505.
21. Zhang K, et al. Melatonin prevents testicular damage in hyperlipidaemic mice. *Andrologia* 2012;44:230-236.
22. Aitken RJ, et al. Generation of reactive oxygen species, lipid peroxidation, and human sperm function. *Biol Repro* 1989;41:183-197.
23. Taysi S, et al. Lipid peroxidation, some extracellular antioxidants, and antioxidant enzymes in serum of patients with rheumatoid arthritis. *Rheumatol Int* 2002;21:200-204.
24. Yang J, et al. Antioxidant enzyme levels in oral squamous cell carcinoma and normal human oral epithelium. *J Oral Pathol Med* 2002;31:71-77.
25. Oberley LW and Oberley TD. Role of antioxidant enzymes in cell immortalization and transformation. *Mol Cell Biochem* 1983;84:147-153.
26. Muruganandan S, et al. Mangiferin protects the streptozotocin-induced oxidative damage to cardiac and renal tissues in rats. *Toxicology* 2002;176:165-173.
27. Cai L, et al. Apoptotic germ-cell death and testicular damage in experimental diabetes: prevention by endothelin antagonism. *Urol Res* 2000;28:342-347.
28. Cameron DF, et al. Interstitial compartment pathology and spermatogenic disruption in testes from impotent diabetic men. *Anat Rec* 1985;213:53-62.
29. Seethalakshmi L, et al. The effect of streptozotocin-induced diabetes on the neuroendocrine-male reproductive tract axis of the adult rat. *J Urol* 1987;138:190-194.
30. Guneli E, et al. Effect of melatonin on testicular damage in streptozotocin-induced diabetes rats. *Eur Surg Res* 2008;40:354-360.
31. Kamani M, et al. Histological Changes of Epididymis of STZ-Induced Diabetic Rats. *Glob J Med Res Stud* 2014;1:122-124.
32. Agarwal A, et al. The role of free radicals and antioxidants in reproduction. *Curr Opin Obstet Gynecol* 2006;18:325-32.
33. Agarwal A and Allamaneni SS. Free radicals and male reproduction. *J Indian Med Assoc* 2011;109:184-187.
34. Agarwal A, et al. Review article: clinical relevance of oxidative stress in male factor infertility: an update. *Am J Reprod Immunol* 2008;59:2-11.
35. Ahmed RG. The physiological and biochemical effects of diabetes on the balance between oxidative stress and antioxidant defense system. *Med J Islamic World Acad Sci* 2005;15:31-42.
36. Ishii H, et al. Gene structures, biochemical characterization and distribution of rat melatonin receptors. *Niger J Physiol Sci* 2009;59:37-47.
37. Lena PJ and Subramanian P. Evaluation of the antiperoxidative effects of melatonin in ammonium acetate-treated Wistar rats. *Pol J Pharmacol* 2003;55:1031-1036.
38. Watala C and Winocour PD. The relationship of chemical modification of membrane proteins and plasma lipoproteins to reduced membrane fluidity of erythrocytes from diabetic subjects. *Clinical Chemistry and Biol Reprod Laboratory Medicine* 1992;30:513-520.