

RESEARCH AND REVIEWS: JOURNAL OF DENTAL SCIENCES

Recalcitrant Proliferative Verrucous Hyperplasia of Palate Transforming Into Squamous Cell Carcinoma: A Diagnostic Emergency.

Kotyanaik Maloth^{1*}, Naga Jyothi Meka², Srikanth Kodangal², and Mithare Sangmesh³.

¹Department of Oral Medicine and Radiology, Mamata Dental College and Hospital, Khammam, Dr. NTR University of Health Sciences, Vijayawada, Andhra Pradesh, India.

²Department of Oral Medicine and Radiology, Sri Sai College Of Dental Surgery, Vikarabad, Dr. NTR University of Health Sciences, Vijayawada, Andhra Pradesh, India.

³Department of Oral Medicine and Radiology, HKDE Dental College and Hospital India.

Case Report

Received: 12/07/2014

Revised : 12/08/2014

Accepted: 24/08/2014

*For Correspondence

Q.NO. B-4/59, NTPC,
Ramagundam 505215,
Telangana, India.
Mobile: +91 8019138210

Keywords: Oral Proliferative verrucous leukoplakia, oral leukoplakia, malignant transformation, oral cancer.

ABSTRACT

Proliferative verrucous leukoplakia (PVL) is a rare and specific variant of oral leukoplakia, different from oral verrucous leukoplakia, principally characterized by chronic proliferation, multiple occurrences, and refractoriness to treatment. Its rate of malignant transformation is extremely high. The aggressive and malignant behavior of Proliferative verrucous leukoplakia sometimes is masqueraded by atypical clinical presentation which can be eliminated by specific diagnostic criteria enlisted by the authors after extensive research. This paper report a case of Proliferative verrucous leukoplakia involving palate with a tendency of rapid transformation towards squamous cell carcinoma clinic-pathologically, emphasizing that all leukoplakia lesions should be closely monitored, even those that initially present nonaggressive behavior.

INTRODUCTION

With the progression of numerous tobacco induced lesions and conditions having inherent precancerous potential depending on the frequency and duration of the habit along with the other predisposing and genetic factors, into more aggressive forms, there arised a need for the early and thorough clinico-pathological evaluation and analysis of certain benign epithelial lesions in the routine clinical diagnostic examinations which subsequently affects the treatment outcome and its prognosis. Way back around 1985, a rare but severe variant of leukoplakia was introduced into the field of oral lesions by Hansen et al ^[1] which was the proliferative verrucous leukoplakia. According to him the term proliferative denotes the clinical behavior of the lesion which tends to be multifocal or diffuse with a tendency to recur after the treatment carrying a high risk of malignant transformation greater than 70%. Until then, this form of verrucous hyperplasia of oral mucosa remained to be an unrecognized and enigmatic variant that may resemble verrucous carcinoma clinically and histopathologically.

Oral leukoplakia (*leuko* = white; *plakia* = patch) is defined by the World Health Organization (WHO) as "a white patch or plaque that cannot be characterized clinically or pathologically as any other disease." The term is strictly a clinical one and does not imply a specific histopathologic tissue alteration ^[2].

Proliferative verrucous leukoplakia is a recently delineated clinical entity which shows a diffuse white and/or papillary (warty) areas of the oral mucosa resulting from varying degrees of epithelial hyperplasia, has the potential to develop into verrucous carcinoma or well differentiated squamous cell carcinoma. Sometimes the clinical presentation shows only the papillary feature lacking a predominant white colour.

According to the latest World Health Organization nomenclature, OPVL conforms to the new terminology of “potentially malignant disorders” given that it is neither a delimited lesion nor a condition [3]. It is best defined as a continuum of oral epithelial disease with hyperkeratosis at one end of a clinical and microscopic spectrum and verrucous carcinoma or squamous cell carcinoma at the other. It is a long-term progressive condition, which develops initially as a white plaque of hyperkeratosis that eventually becomes a multifocal disease with confluent, exophytic and proliferative features and behaves in a more aggressive and relentless manner than the more innocuous white oral lesions that it can resemble clinically [4].

Owing to its potential malignant behaviour compared to the conventional oral leukoplakia, researchers after their tremendous efforts, formulated certain specific clinical and histopathological criteria to eliminate diagnostic dilemma among the oral premalignant lesions, however, the genetic and molecular mechanisms underlying this variant is still a topic of debate. With this background, we report a case of Proliferative verrucous leukoplakia involving palate with a tendency of rapid transformation towards squamous cell carcinoma clinicopathologically, emphasizing that all leukoplakia lesions should be closely monitored, even those that initially present nonaggressive behavior.

Case history

An 80 year old female patient reported with a chief complaint of looseness of teeth on upper front tooth region and a white patch on the palate, since 2yrs (Figure1). Initially it started as small white patch which progressed to present size; there is no history of pain, no paraesthesia and no bleeding. But since 1year a swelling started in the upper edentulous region which elicited pain. Habit of pan chewing since 6yrs (10 pans per day) with zarda and slaked lime. No relevant medical history. Lymph nodes were not palpable. On intra oral examination a diffuse white patch is seen on the right half of the hard palate, measuring approx. 5 × 3 cm in size. It extends antero-posteriorly from mesial half of 21 to distal half of 17 and medio-laterally it extends middle half of the hard palate to right side of the buccal and labial vestibules. No discharge and no bleeding are noticed. On palpation the surface is rough, granular and raised (Figure 2). Induration was felt at the anterior region of labial alveolus. Pain was elicited on labial alveolus. No bleeding was noticed on palpation. On dental examination there was missing tooth from 11 to 17. And grade III mobility was seen irt 21. Based upon the clinical features provisional diagnosis of Proliferative Verrucous Leukoplakia was given. Differential Diagnosis of Verrucous hyperplasia, verrucous carcinoma, hyperplastic candidiasis, papilloma, condyloma acuminatum, was considered.

Routine blood investigations were done which was in normal limits. Radiological investigations were done and intraoral periapical radiograph of edentulous region irt missing 11, 12, 13 was better visualized and it showed superficial erosion of bone (Figure 3). Maxillary occlusal radiograph reveals destruction of bone on right alveolus and right half of the anterior part of hard palate (Figure 4). Incisional biopsy was done from labial alveolus (Figure 5).

Histopathologically, it consisted of sheets and nests of cells with characteristic appearance of squamous origin. Nuclei were distinctly dark stained. There were increased numbers of mitotic figures but relatively few from moderately differentiated carcinoma. It showed hyperchromatism prominent and multiple nuclei and increased nucleo-cytoplasmic ratio, suggestive of *well-differentiated superficially invasive squamous cell carcinoma* (Figure 6). A final diagnosis of Carcinoma of right maxillary alveolus irt edentulous 11, 12, 13 region and hard palate was given. Patient referred to the government cancer institute where she was advised for Chemotherapy.

Figure 1: Profile photograph

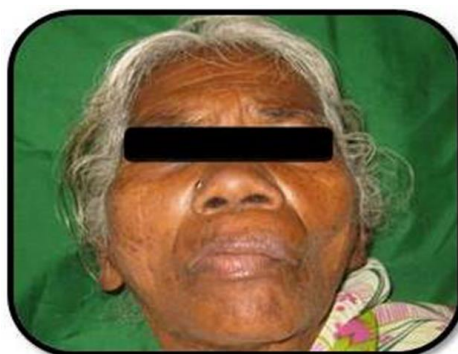

Figure 2: Intra-oral photograph showing white patch on the hard palate.

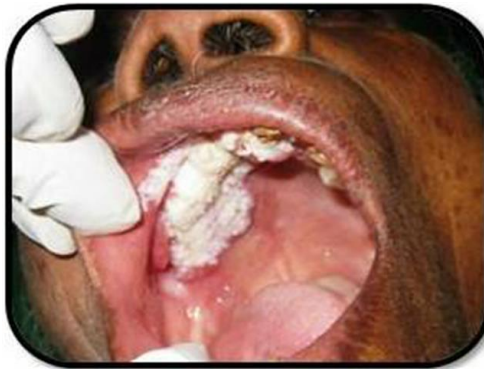

Figure 3: Intraoral periapical radiograph.

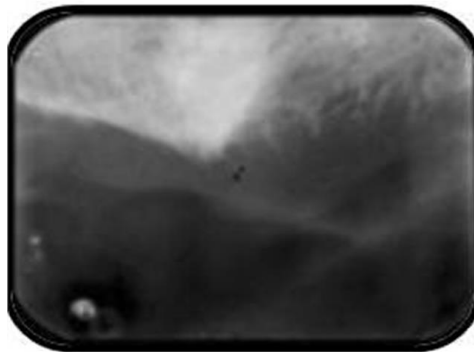


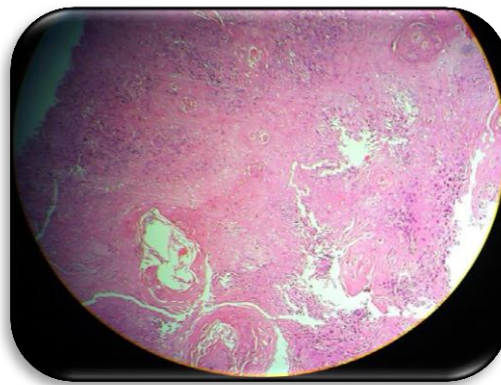
Figure 4: Maxillary occlusal radiograph reveal destruction of bone on right alveolus & part of hard palate.

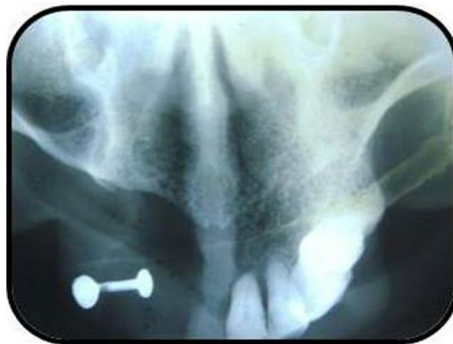

Figure 5: Incisional biopsy

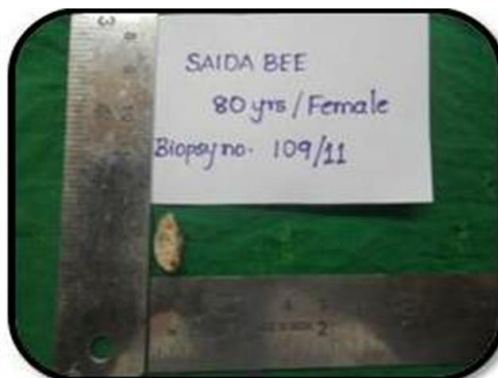

Figure 6: Histopathological picture.



DISCUSSION

Proliferative verrucous leukoplakia (PVL) is a rare and specific variant of oral leukoplakia, different from oral verrucous leukoplakia, principally characterized by chronic proliferation, multiple occurrences, and refractoriness to treatment. Its rate of malignant transformation is extremely high [1]. It is a recently delineated clinical entity that occurs predominantly in older individuals with a female predilection (4:1 female to male ratio). PVL grows slowly and can take up to 7.8 years to become cancerous. The process is irreversible and usually progresses to cancer. According to the study by Bagan, PVL quickly becomes malignant, on average within 4.7 years [5], whereas Hansen in his follow up study reported an average time to cancer of 6.1 years [1]. However, Silverman and Gorsky reported a longer mean malignant process of 11.6 years [6]. The common oral sites involved are buccal mucosa, palate, gingival and tongue.

The etiology is still unclear and seems to be idiopathic. Smoking and alcohol consumption doesn't attribute to these lesions which are the primary risk factors for the oral leukoplakia as PVL occur in both smokers and non-smokers [7]. An association between PVL and HPV-16 & 18 has been reported though not proved yet.

The proliferative effect of PVL and its protracted clinical course was explained on basis of the high rate of field cancerization existing in PVL patients [8]. Several authors have reported that genetic factors and immunologic factors should be implicated in the malignant transformation of PVL more than local predisposing factors.

PVL as described by Hansen develops through a histopathological continuum encompassing 10 stages from - normal oral mucosa (0), homogeneous leukoplakia (2), verrucous hyperplasia (4), verrucous carcinoma (6), papillary squamous cell carcinoma (8), and poorly differentiated carcinoma (10), in which the odd scores refer to a status intermediate between those referred to a status intermediate between those referred to by the adjacent even scores [1].

Batsakis et al reduced the number of histologic stages to 4 with intermediates:

Grade 0: Clinical flat leukoplakia without dysplasia.

Grade 2: Verrucous hyperplasia

Grade 4: Verrucous carcinoma

Grade 6: Conventional squamous cell carcinoma with intermediates [9].

Early phase of these lesions usually exhibits an interface lymphocytic infiltrate showing a pronounced lichenoid pattern characterized by basal vacuolar degeneration containing apoptotic cells and eosinophilic bodies, similar to types of oral lichenoid stomatitis such as lichen planus [10].

To eliminate the misdiagnosis and late interventions, Cerero-Lapiedra et al in 2010 [4] proposed the following major and minor diagnostic criteria for PVL. **(Table 1)**

Modified diagnostic criteria for PVL; all four criteria should be met. **(Table 2)**

Table 1

Major criteria (MC)	Minor criteria (mc)
A leukoplakia lesion with more than two different oral sites, which is most frequently found in the gingiva, alveolar processes and palate.	An oral leukoplakia lesion that occupies at least 3 cm when adding all the affected areas.
The existence of a verrucous area.	That the patient be female
That the lesions have spread or engrossed during development of the disease.	That the patient (male or female) be a non-smoker.
That there has been a recurrence in a previously treated area.	A disease evolution higher than 5 years.
Histopathologically, there can be from simple epithelial hyperkeratosis to verrucous hyperplasia, verrucous carcinoma or oral squamous cell carcinoma, whether in situ or infiltrating.	

Table 2: Modified diagnostic criteria for PVL

1.	Leukoplakia showing the presence of verrucous or wartlike areas, involving more than two oral subsites. The following oral subsites are recognized: dorsum of the tongue (unilateral or bilateral), border of the tongue, cheek mucosa, alveolar mucosa or gingiva upper jaw, alveolar mucosa or gingiva lower jaw. hard and soft palate, floor of the mouth, upper lip and lower lip
2.	When adding all involved sites the minimum size should be at least three centimeters
3.	A well-documented period of disease evolution of at least five years, being characterized by spreading and enlarging and the occurrence of one or more recurrences in a previously treated area
4.	The availability of at least one biopsy in order to rule out the presence of a verrucous carcinoma or squamous cell carcinoma

Nevertheless, at present, there is no criterion that will allow for the early diagnosis of the disease [11].

Clinical Fate of Proliferative verrucous leukoplakia

OPVL is known for its aggressive [12] pathology and biology, attributed to its multifocal involvement explained by the concept of field cancerization, high malignant transformation rates (60-100%), frequent recurrences (87-100%) and high mortality rates (30-50%) [13]. The gingiva and palate represented the areas with the highest frequency of these multiple malignant tumors.⁴ Given the high tendency for (OSCCs) to appear in these patients, they should be checked for life at least once every 6 months [8].

Various treatment modalities are proposed for PVL which include complete removal accomplished by conventional surgery, radiotherapy, cryotherapy, vitamin A therapy, antiviral therapy, or recent techniques by carbon dioxide laser surgery and photodynamic therapy. Early trials of topical chemotherapy with bleomycin have been assessed but none has proven to be curative till now [14]. Long term follow up after removal is extremely important because recurrences are frequent and because additional leukoplakia may develop. The possible complication is the high rate of malignant transformation, the lack of a successful treatment, and the number of recurrences after management. Antiviral methisoprinol appeared to offer a significant benefit [15]. In the future, anti-HPV, anti-TGF, and pro-apoptotic management strategies may be considered.

CONCLUSION

The importance of the diagnosis of PVL lies in the awareness of both the clinician and pathologist that apparently innocent looking oral verrucous lesions, irrespective of their colour and irrespective of the presence of dysplasia may in time progress into verrucous carcinoma or squamous cell carcinoma.

REFERENCES

1. Hansen LS, Olson JA, Silverman S. Proliferative verrucous leukoplakia. *Oral Surg Oral Med Oral Path.* 1985; 60:285-98.
2. Neville, Damm, Allen, Bouquot, *Oral and maxillofacial pathology* 3rd edn, Saunders. pp 388- 397, 422- 423.
3. Warnakulasuriya S, Johnson NW, Van der Waal I. Nomenclature and classification of potentially malignant disorders of the oral mucosa. *J Oral Pathol Med.* 2007; 36:575-80.

4. Cerero-Lapiedra R, Balade-Martinez D, Moreno-Lopez LA, Esparza-Gomez G, Bagán JV. Proliferative verrucous leukoplakia: A proposal for diagnostic criteria. *Med Oral Patol Oral Cir Bucal*. 2010; 15:e839-45.
5. Bagan JV et al. Proliferative verrucous leukoplakia: high incidence of gingival squamous cell carcinoma. *J Oral Pathol Med*. 2003; 32(7):379-382.
6. Silverman S, Gorsky M. Proliferative verrucous leukoplakia: A follow-up study of 54 cases. *Oral Surg Oral Med Oral Pathol Oral Radiol Endod*. 1997; 84:154-157.
7. Shewale VN, Shewale K. Proliferative verrucous leukoplakia: Benignly progressing towards malignancy. *Asian J Oral Health Allied Sci*. 2011;1:71-3.
8. Bagan JV et al. Proliferative verrucous leukoplakia: unusual locations of oral squamous cell carcinomas, and field cancerization as shown by the appearance of multiple OSCCs. *Oral Oncol*. 2004; 40:440-443.
9. Batsakis JG, Suarez P, EL- Naggar AK. Proliferative Verrucous Leukoplakia and its related lesions. *Oral Oncol*. 1999; 35:354.
10. Mete O, Keskin Y, Hafiz G, Kayhan KB, Unur M. Oral proliferative verrucous leukoplakia: Underdiagnosed oral precursor lesion that requires retrospective clinicopathological correlation. *Dermatol Online J* 2010; 16:6.
11. Gandolfo S, Castellani R, Pentenero M. Proliferative verrucous leukoplakia: A potentially malignant disorder involving periodontal sites. *J Periodontol*. 2009; 80:274-281.
12. Navarro CM, Sposto MR, Sgavioli-Massucato EM, Onofre MA. Transformation of proliferative verrucous leukoplakia to oral carcinoma: A ten years follow-up. *Med Oral*. 2004; 9:229-233.
13. Kresty LA, et al. Frequent alterations of p16INK4a and p14ARF in oral proliferative verrucous leukoplakia. *Cancer Epidemiol Biomarkers Prev*. 2008; 17:3179-3187.
14. Robert JC, Thomas HM, Joel BE. Proliferative verrucous leukoplakia and its progression to oral carcinoma: a review of the literature. *J oral Pathol Med*. 2007; 36:255-261.
15. Femiano F, Gombos F, Scully C. Oral proliferative verrucous leukoplakia: open trial of surgery compared with combined therapy using surgery and methisoprinol in papillomavirus-related PVL. *Int J Oral Maxillofac Surg*. 2001; 30(4):318-22.