

Research & Reviews: Journal of Dental Sciences

Prevalence of Exostoses in Yucatan Maya Ascent Patients

Ricardo Penaloza-Cuevas^{1*}, Celia Mendiburu-Zavala², Ruben Cardenas-Erosa², Lilian Aguilar-Vera²,
Jessica Ancona- Alcocer², Alberto Rivero-Navarrete ME²

¹M.D. University Autonoma de Yucatan, Mexico

²Restorative Dentistry, Academic Department of the Dentistry Faculty at the Universidad Autonoma de Yucatan, Mexico

Research Article

Received date: 11/11/2015

Accepted date: 23/01/2016

Published date: 01/02/2016

*For Correspondence

Dr. Ricardo Penaloza-Cuevas, M.D.
University Autonoma de Yucatan, Mexico.

E-mail: pecuevas@correo.uady.mx

Keywords: Exostoses, Torus, Mayan population

ABSTRACT

The aim of this study is to define the Prevalence of exostoses in Yucatan Mayan ascent patients from the Universidad Autonoma de Yucatan (UADY) Dental Faculty, during a 3-month period. Yucatan is the state with highest Mayan ethnic concentration, characterized by a brachiocephalic-exostoses association. Bony asymptomatic anatomical variation growths, located in jaws, resulting of genetic-environmental interaction factors.

Methods: Observational, descriptive study, including 122 Yucatan Mayan ascent patients, between 21 and 80 years old. Mayan ascent-based confirmed thru last name verification of two generations back. Data obtained from intraoral examination, recording exostoses location and morphology. Statistical descriptive analysis and chi-square test was performed.

Results: Of the 122 patients studied, 25 (20.49%) had exostoses; 68% female 32% male; 28% palatal torus; 36% mandibular torus and 4% vestibular exostoses; 32% in both arches. Shape showed 33% were unilobular flat torus, 27% lobular, 6% nodular, and 34% spindle-shaped. Concerning mandibular torus, 39% unilateral and 61 % bilateral. Prevalence ranges from 13.7% to 28.7% ($p = 0.0142$), considered statistically significant.

Conclusions: There are few studies reporting Mayan population exostoses prevalence, but the results obtained represent a prevalence three times higher than current literature. The potential use of exostoses as sources of autogenous cortical bone for grafting.

INTRODUCTION

Mayan population has influence in the southeast of Mexico especially in the Yucatan Peninsula area (Yucatan, Campeche, Quintana Roo states), Chiapas, and Central American countries (Guatemala and Belize). The National Indigenous Language Institute estimates the presence of 759,000 speakers of Mayan languages in Mexico; most of them living in Yucatan ^[1]. The National Institute of Statistics, Geography and Information (INEGI), reported that between 15% and 30% of the population in Yucatan are of Mayan ascent and speakers of the native language ^[2].

Morley SG defines the Mayan as a population characterized by an average height of 154.61 cm and 142.65 cm, weight of 52.86 kg and 50 kg and a cephalic index average of 85.8 and 86.8 for males and females respectively ^[3]. Based on archaeological evidence, the Mayan have a wide-flat forehead, wide head (brachycephalic), aquiline nose, straight black hair, high cheekbones, and almond-shaped dark eyes, short neck and broad shoulders ^[4]. Cucina A mentions that the brachiocephalic skeleton includes individuals with short antero-posterior skulls, forming a round head, due to a diameter, where the length is almost equal in size to the width ^[3].

Environmental factors, such as soil and hydrology of the Yucatan Peninsula could be associated to the presence of exostoses. The soil consists of limestone, with sandstone that can contain shell material on the coastal area. The lower parts have soils with

low permeability coupled with high humidity and proximity to cenotes (natural pits or sinkholes, resulting from the collapse of limestone bedrock that exposes groundwater underneath), factors that are prone to cause flooding and emerging gleysols. These soils contain large amounts of organic material, which explains its low alkalinity [5].

The hydrology of Yucatan coast lagoons are directly correlated with a loading and nutrient dynamics, both associated to contributions from groundwater and wastewater. The relevance of this data stems from the fact that the inhabiting Mayan population, still drink the described water which contains various mineral deposits; condition that could be associated to the appearance of exostoses in the oral cavity [6].

Exostoses are bony, generally asymptomatic, slow development benign outgrowths, considered an anatomical variation and not a pathological condition. When located in palatal surface of the upper jaw they are named: palatal torus (TP), and if located in the lingual mandible surface, mandibular torus (TM) [7,8].

Both the palatal and mandibular torus can develop in two ways: lobular, surrounded by a pedunculated lobular mass that can arise from a single-surface base; and multi-lobular, with multiple protuberances each with its own single-surface base [8]. Palatal torus are developed in the midline of the hard palate as increased of volume circumscribed stony, hard consistency, with a very thin underlying mucosa (normal pink to pale pink). Shape can be: flat, lobular, nodular and spindle-shaped [8,9].

Mandibular torus are observed in the lingual aspect of the mandible, with variations in shape and size. They may be bilateral in more than 80 % and mainly located in the premolar region [9].

Thru x-rays, hemispherical radio opacity is observed on the alveolar ridge. When size is less than 4 mm exostoses are not detected. Histologically exostoses are observed as an adult bone cortex structure, with small stroma and marrow spaces. The differential diagnosis should consider palatal abscess, salivary gland tumors and lymphomas [10-12].





Exostoses prevalence worldwide is varied but on average, it reports at 6.7%. However high data have been reported in European and Asian-oseanic populations 46%; 26% African and south-American and African-Americans had about 25%. In Yucatan a first mixed population study reported 6.7% while in a Mayan population registered a 18.68% [12-14].

The aim of this study was to determine the prevalence of exostoses in Yucatecan Mayan ascents.

MATERIALS AND METHODS

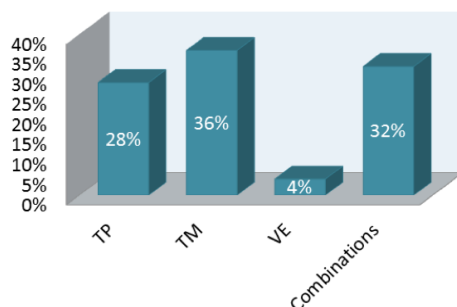
An observational, descriptive and cross-sectional study was performed. Informed consents were given to patients that participated. The study included Yucatecan Mayan ascent patients with three previous generations including patient, both parents and grandparents, between 21 and 80 years old who assisted to the dentistry school of the UADY, during October 2013 to January 2014. Each patient underwent intraoral clinical examination (NOM 013). For data compilation an instrument was designed containing the general personal patient data and ethnicity; presence or not of exostoses; location unilateral or bilateral in maxilla or jaw and if it was in an anterior, medium or posterior of them; shape (lobular plane, lobulillar, nodular or spindle) and number of lobes (Table 1) [15]. For analysis descriptive statistics and chi-square test were used.

Table 1. Messuring instrument of exostoses in Maya ascent patients, Yucatan, Mexico 2014.

UNIVERSIDAD AUTONOMA DE YUCATAN							
Name:		Age:		date:			
#HC:		Sex: M <input type="checkbox"/> F <input type="checkbox"/>		Clinic:			
City of birth:				Residence city:			
Patient:							
Fathers:							
Grandfathers:							
Exostoses:		yes <input type="checkbox"/> no <input type="checkbox"/>		* If the answer was yes, continue filling			
Maxila Exostoses <input type="checkbox"/> PT <input type="checkbox"/>				Jaw Exostoses <input type="checkbox"/> MT <input type="checkbox"/>			
Location	Anterior <input type="checkbox"/>	Medio <input type="checkbox"/>	Posterior <input type="checkbox"/>	Anterior <input type="checkbox"/>	Median <input type="checkbox"/>	Posterior <input type="checkbox"/>	
Shape	<input type="checkbox"/> Lobular Plane 			<input type="checkbox"/> Unilateral		<input type="checkbox"/> Bilateral	
	<input type="checkbox"/> Lobulillar 			Number of lobes:		Number of lobes:	
	<input type="checkbox"/> Nodular 			Right	left	right	left
	<input type="checkbox"/> Spindle 						

RESULTS

A population of 845 patients, 122 Mayan ascent were studied. 20.49% (n = 25) showed exostoses, 68% female and 32% male. In terms of location, data is showed in **(Figure 1)**.

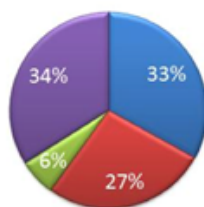


Graphic 1. Exostoses prevalence according to location in the oral cavity

Figure 1. Exostoses Prevalence according to location in the oral cavity.

Regarding the shape and location of the exostoses are shown in **(Figures 2 and 3)**.

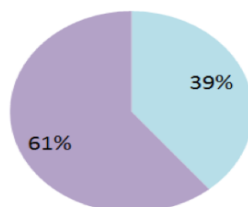
■ Flat ■ Lobular ■ Nodular ■ Spindle shaped



Graphic 2. Prevalence of torus palatinus according to shape

Figure 2. Prevalence of torus palatinus according to shape.

■ Unilobular ■ Multilobular



Graphic 3. Prevalence of torus mandibularis according to shape

Figure 3. Prevalence of torus mandibularis according to shape.

With 95% of confidence, it can be inferred that the prevalence of patients with exostoses in Mayan ascent is between 13.7% and 28.7%. Distribution by chi-square test showed that sex and shape of exostoses are dependent, statistically with an error of 0.05 **(Table 2)**.

Table 2. Distribution of exostoses according to gender.

Gender	No Exostoses			Shape of Exostoses			Total
	No Exostoses	Flat	Lobular	Nodular	Spindle shaped	Multilobular	
Male	44	0	1	0	1	7	53
	36.07 %	0 %	0.82 %	0 %	0.82 %	5.74 %	43.44 %
Female	51	8	1	3	4	2	69
	41.80 %	6.56 %	0.82 %	2.46 %	3.28 %	1.64 %	56.56 %
Total	95	8	2	3	5	9	122
	77.87 %	6.56 %	1.64 %	2.46 %	4.10 %	7.38 %	100 %

DISCUSSION

This study reported an exostoses prevalence (20.49%) similar to Nunes' observations (20%) in Brazilian and Latin American population and Guzman (22.16%) in a Colombian population. However Sinistierra reported a 10% in another Colombian population and Meisser a 79.9% in the same country but in a different areas. While Simunkovic in Croatia reported 55.5% and Jainkittivong in Thailand 26.9% [16-18].

Gender reported a higher prevalence in female 68% (17 cases) and male 32% (8 cases) similar to that reported by Guzman in Colombia (57.1% female, (42.9%) male. In contrast to Simunkovic how reported 61.4% in male and Jainkittivong with 62.4%^[17-19].

Regarding age, it was found that the group 41-60 years reported more frequently coincide with Jainkittivong and Eggen. However, Nunes and Mannotas recorded the highest frequency at ages 21-30 and 14-17 respectively^[16-20].

Meza in Washington DC, reported the torus presence in women of different ethnicity. 448 women aged 18-88 years were studied: 302 African-American, 62 Caucasian, 43 Hispanic, 36 Asian and 5 Native American. Torus was detected in 107 African Americans (35.4%), 20 Caucasians (32.3%), 13 Hispanics (30.2%) Asian 14 (38.9%) and in 1 of the 5 native (20%)^[21].

According to the location in the mouth: Mandibular Torus (36%) showed a higher prevalence, 61% bilateral and 39% unilateral, coinciding with Guzman how reported Mandibular Torus (66.2%): 74.1% bilateral and 26.9% unilateral and Al Quran, TM (42.6%) and TP (29.8%). However Simunkovic (42.9%) Nunes (60%) and Meisser (47.3%) found a highest prevalence in TP^[16,17,19,22].

Regarding the morphology, TP shaped spindle reported (33%) similar to that reported by Simunkovic, who recorded 45.6%, contrasting with Mannotas where flat lobular shape prevailed (24.7%)^[17-20].

CONCLUSIONS

With 95% confidence it can be inferred that the prevalence of patients with exostosis of Mayan ascent is statistically significant.

In a previous research in a mixed population at the FOUADY prevalence found was 6.7% similar to the world literature. In the actual study in Mayan population it reached to 20% three times more.

No standardized instrument for recording data is available in literature for exostoses that contains the sex, location, shape, number, so in this article a unifide format for data collection is proposed.

REFERENCES

1. Mendiburu-Zavala C and Casanova R. Prevalence of root canals of mandibular second molars in a contemporary Maya population. *Inter J Dental Anthropol.* 2013;22:14-23.
2. INEGI. Pagina del Instituto Nacional de Estadística y Geografía. 2015.
3. Cucina A. Population dynamics and biological affinities among the ancient Maya. A multidisciplinary vision, Merida Yucatan. Autonomous University of Yucatan. 2013.
4. Cucina A. Biological variability in the Maya area during the Classic and Postclassic from the dental morphology. Merida Yucatan. Autonomous University of Yucatan. 2013.
5. Aguilera IMCO. Special Climate Change for the period 2012-2020 with additional actions and potential analysis program. Semarnat, Mexico. 2012.
6. Diaz A, et al. Environmental Diagnosis of the Gulf of Mexico. Executive Summary. Environmental diagnosis of the Gulf of Mexico. Secretariat of Environment and Natural Resources, National Institute of Ecology. Institute of Ecology, Mexico. 2007.
7. Sinisterra G, et al. Spontaneous exhibition of a torus palatine midline. *biomedical.* 2013;33:31-35.
8. Fuentes R, et al. Oral presence of exostosis in patients from the city of Temuco, Chile. *Av Odontostomatol.* 2012;28:57-62.
9. Batista T, et al. Palatal mandibular torus and in patients treated at the Polyclinic Pedro Diaz Coello. *CCM.* 2013;17:1-7.
10. Vicente J, et al. Torus mandibular. *Rev Clinic Family Medicine.* 2006;1:242-244.
11. Cava C, et al. Removal of palatal torus by dysmorphic thought. 2008;5:73-77.
12. Smitha K and Smitha G. Alveolar Exostosis revisited: A narrative review of the literature. *The Saudi Journal for Dental Research.* 2014;6:67-72.
13. Penaloza-Cuevas R, et al. Prevalence of exostosis in patients attending the Faculty of Dentistry at the University of Yucatan (FOUADY). *Rev Odontol Latinoam.* 2013;5:7-12.
14. Lazaro El. Prevalence of maxillary exostosis in patients of the health center, Samagil, Yucatan. 2013.
15. Official Mexican Standard NOM- 013- SSA2-2006 for the prevention and control of oral diseases. *Official Gazette.* 2006.
16. Nunes A, et al. Correlation between the presence of exostosis and temporomandibular dysfunction. *Journal of Health Promotion.* 2008;21:174-179.
17. Simunkovic SK, et al. Prevalence of torus palatinus and torus mandibularis in the Split-Dalmatian Country, Croatia. *Coll Antropol.* 2011;35:637-641.
18. Jainkittivong A and Langlais R. Buccal and Palatal exostoses: Prevalence and concurrence with tori. *Oral Surg Oral Med Pathol Radiol Endod.* 2000;90:48-53.

19. Guzman B, et al. The torus in oral cavity findings in a sample population of Santiago de Cali. *Gastrohnup magazine*. 2014;16:95-100
20. Manotas I and Estevez EA. Palatal torus, mandibular torus and exostosis of the jaw in patients of the dental clinic of the University of Magdalena. *Rev Biomed Cienc*. 2010;1:47-53.
21. Meza JL. Oral Cavity and torus Torus Palatinus mandibularis. *Rev Gastroenterol*. 2004;24:343-348.
22. Quran AI, et al. Torus Palatinus and Torus Mandibularis in Edentulous Patients. *J Contemp Dent Pract*. 2006;7:112-119.