

# Research & Reviews: Journal of Hospital and Clinical Pharmacy

## Person Infected with Maggots of Banded Blowfly *Chrysomya albiceps* and Latrine Fly *Chrysomya megacephala*

Shuvra Kanti Sinha<sup>1\*</sup>, Prabhat Chandra Mondal<sup>2</sup>, Santanu Mahato<sup>1</sup>

<sup>1</sup>Calyprate Research Laboratory, Department of Zoology, Sonamukhi College, India

<sup>2</sup>Department of Gynecology and Obstetrics, Bankura Sammilani Medical College & Hospital, India

### Case Report

**Received date:** 25/01/2016

**Accepted date:** 29/02/2016

**Published date:** 05/03/2016

#### \*For Correspondence

Shuvra Kanti Sinha, Calyprate Research Laboratory, Department of Zoology, Sonamukhi College, Sonamukhi, West Bengal, India

**Email:** suvrosinha@gmail.com

**E-mail:** Cutaneous myiasis, *Chrysomya albiceps* (Wiedemann), *Chrysomya megacephala* (Fabricius).

#### ABSTRACT

A case of cutaneous myiasis caused by *Chrysomya albiceps* (Wiedemann) and *Chrysomya megacephala* (Fabricius) was reported.

### INTRODUCTION

According to Hope <sup>[1]</sup> myiasis is a disease of human beings originated specially with dipterous larvae. Zumpt <sup>[2]</sup> defined myiasis as “the infestation of live vertebrate animals with dipterous larvae, which at least for a certain period, feed on host’s dead or living tissues, liquid body substances or ingested food”. These invasions may be benign in effect or may result in mild to violent disturbances, even death. Flies belonging to family Calliphoridae mostly cause traumatic and wound myiasis Roy <sup>[3]</sup>. The present paper reports a case of cutaneous wound myiasis of a person caused by maggots of family Calliphoridae.

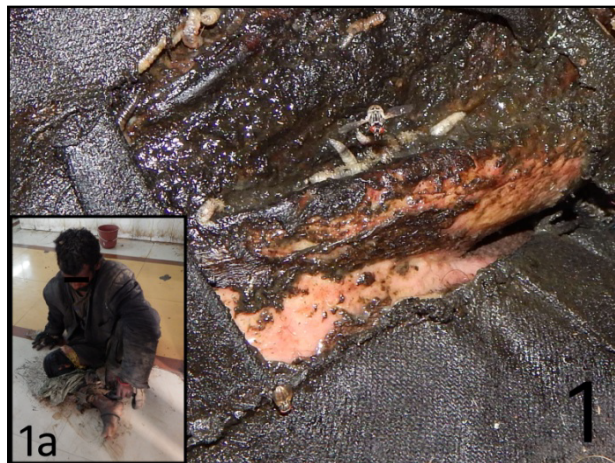### CASE REPORT

A mental disabled person was forced to admit in a hospital in Bankura District of West Bengal, India for treatment. Clinical observation revealed that the infection on the knees and ankles of the right leg of the person was involved by many maggots of different developmental maturity. The patient with wounded knees and ankles remained separate from other patients of the ward because of foul smell. Maggots were found to crawl around the wound and some larvae were migrating to the corners of the room. The crawling maggots were collected from the patient’s body and some were collected from the wound. Then the maggots were reared on fresh and raw chicken meat in the laboratory maintaining suitable conditions. After pupation, the pupae were kept in a humid environment under moist saw dust. The emerged adult flies were identified by study of adult morphology and genitalia. Entomological studies revealed that the maggots were of two different fly species, *Chrysomya albiceps* (Wiedemann) and *Chrysomya megacephala* (Fabricius).


### DISCUSSION

*Chrysomya albiceps* (Wiedemann) commonly known as banded blowfly is extremely common in the subtropical parts of Africa, in Asia Minor and Palestine and around the shores of the Mediterranean Sea (Senior-White et al., 1940). It is a facultative

parasite and normally lays its eggs on carcasses. The first instar maggots feed on exudations of the decomposing flesh. The eggs may also be laid on neglected wounds where the larvae can cause tissue destruction. There was no previous report regarding distribution of *Chrysomya albiceps* (Wiedemann) in West Bengal of India. *Chrysomya megacephala* (Fabricius), the latrine fly is widespread throughout India and South East Asia with many recent introductions in many parts of the world. The larvae of this fly species develop generally in carrion or on dead and decomposed tissues [4] *Chrysomya megacephala* (Fabricius) also involve in myiasis [5]. The larvae of this fly caused umbilical myiasis in neonate [6] and aural myiasis [3]. **(Figures 1 and 2).**



**Figure 1.** Maggot infected knee of the patient. 1a. Patient



**Figure 2.** Maggot (2a) and Pupa (2b) of *C. albiceps* (Wiedemann), collected larva (3a) and Pupa (3b) of *C. megacephala* (Fabricius) (Scale in Milimeters)

It was believed that the patient was used to live in an unhygienic condition without bathing for a long time. Keeping such an unpleasant smell and improper sanitation, he might invite the flies to be attracted and deposited eggs in his body and foul smelling cloths or on the previously existing wounds. Maggot infestation was so painful and drastic in this case that it took several months to heal the wound completely. The wounds were dressed regularly with normal saline. Antibiotics were prescribed according to the culture sensitivity report. After two months of extensive treatment, all the wounds became healed. The patient was shifted to a charity home, where he would be looked after by some trained persons for his early come back to his society.

## REFERENCES

1. Hope FW. On insects and their larvae occasionally found in the human body. *Trans R Entomol Soc Lond.* 1840;2:256-271.
2. Zumpt F. *Myiasis in man and animals in the old world: Butter worths.* 1965.
3. Roy P and Dasgupta B. Myiasis in domestic animals in Siliguri. *J Beng Nat Hist Soc.* 1982;1:44-51.
4. Rahoma AH and Latif B. Human foot myiasis in Malaysia with a review of the literature *J. Trop Med Parasitol.* 2010;33:41-43.
5. Spradbery JP. *A manual for the diagnosis of screw-worm fly.* Department of agriculture, Fisheries and Forestry Australia. 2002;p:17.
6. Mondal M, et al. Umbilical myiasis with sepsis in a neonate. *Asian Journal of Medical Sciences.* 2014;5:106-107.