

Research & Reviews: Journal of Medical and Health Sciences

Myopia or Short Sightedness—A Review

Maithri G*

*MS, Pharmacoinformatics, National Institute of Pharmaceutical Education and Research, Kolkata, India

Review Article

Received: 02/09/2016

Accepted: 23/09/2016

Published: 28/09/2016

*For Correspondence

Maithri Gundaram, MS,
Pharmacoinformatics, National
Institute of Pharmaceutical
Education and Research,
Kolkata, India, Email:
Mythri059@gmail.com

Keywords: Myopia, Short
Sightedness, Eye diseases

ABSTRACT

Myopia, also known as short-sightedness or Near-sightedness. It is a condition of the eye where light Centre in front, instead of on the retina. Myopia causes long distant things to be blurry while close entity appear normal. In this case we can usually see symptoms like headaches and eye strain. Most of the short-sightedness increases the chance of getting retinal detachment, cataracts, and glaucoma. The reduced in age of arrival of myopia is of well treated since the beginning. If myopic the individual will become more in number, then with all the porter increased risks of escort debilitating eye conditions. At beginning levels myopia expand the lifetime economic burden related to loss of efficiency and self-dependence, foremost to a minimize quality of life. Novel data direct the accommodation per se has little direct improvement of myopia condition. Pharmacological involvement that effect modifications in the sclera show promising action, whereas optical intercession depends on a myopic shift in the retinal image are demonstrate effect up to 50% decrease in the progression rate of myopia condition. At present contact lens and spectacle helps to reduce the short-sightedness and are able to notably lower the burden of myopia. These non-pharmacological involvements indicate us regards lowering the overall associated specific action of myopia disease.

INTRODUCTION

Myopia is a Greek work, which literally means "trying to see like a mole". In American English it is termed as 'near-sightedness' and in British English 'short-sightedness' [1-9]. Myopia can be defined as a condition of the eye where, the light that enters does not directly focus on the retina but in front of it, which lead to the image that one sees when looking at a distant object to be out of focus, but in focus when looking at a close object.

STRUCTURES AND PREPARATION METHODS OF NLCs

Symptoms

In normal myopic condition, the persons distance vision become blurry (Figure 1), but generally gives well near vision. In high myopic condition, even the near vision is affected, therefore to see the objects clearly, one must hold the object very close to the eyes. It becomes very difficult to read without their glasses prescribed for distance [10-15]. In myopic condition, the optic nerve becomes tilted and a portion of white sclera could be seen on next to the disc along with a line of hyperpigmentation, which could be seen separated from the retina. The macula gets some retinal pigmentary changes along with sub retinal hemorrhages [16]. In this condition, the retina becomes thin can even be spotted retinal holes along with lattice degeneration on thorough checking and examination. There is also a chance of development of choroidal neovascularization in the macula [17-21].

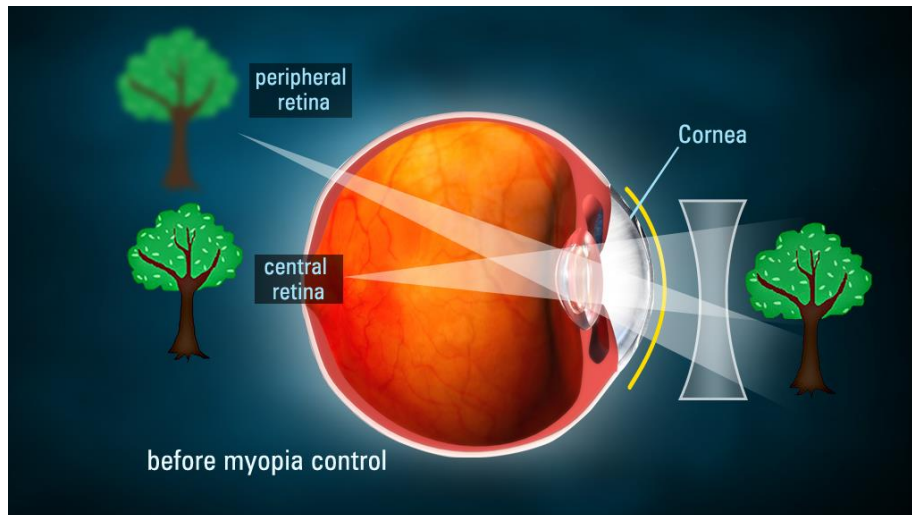


Figure 1: Myopia condition (Blurred vision).

Treatment and care

The ophthalmologists generally prefer the use of corrective lenses for the correction of myopia, which could be either glasses or contact lenses [21-30]. Myopia can also be corrected by refractive surgery, although there might be some side effects. The corrective lenses have a negative optical power (i.e. have a net concave effect) which compensates for the excessive positive diopters of the myopic eye [31-36]. Negative diopters are generally used to describe the severity of the myopia, as this is the value of the lens to correct the eye. High-degree myopia, or severe myopia, is defined as -6 diopters or worse [37-42].

Types

The types of myopia can be divided on many basis, they are.

- By cause
- Clinical entity
- Degree
- Age at onset

Myopia can be divided on the basis of cause

Axial myopia: It occurs due to the increase in the axial length of eye [43-45].

Refractive myopia: It occurs due to the condition of the refractive elements of the eye. Borish further sub classified refractive myopia [46-51].

- i. **Curvature myopia:** It occurs due to increase in curvature of one or more of the refractive surfaces of the eye, especially the cornea.
- ii. **Index myopia:** It occurs due to the variation in the refractive index of one or more of the ocular media.

On the basis of Clinical entity, myopia can be divided as

- i. **Simple myopia:** The most common type of myopia, in which an eye that is too long for its optical power or optically too powerful for its axial length [52-57].
- ii. **Degenerative myopia:** It is also known as malignant, pathological, or progressive myopia is characterized by marked fundus changes, such as posterior staphyloma, and associated with a high refractive error and subnormal visual acuity after correction [58-66].

- iii. **Nocturnal myopia:** It is also known as night or twilight myopia, in which it becomes difficult to see in dark areas or not well lighted areas [67-72].
- iv. **Pseudomyopia:** It occurs due to the spasm of the ciliary muscle.
- v. **Induced myopia:** It occurs due to various anomalous conditions, such as exposure to various pharmaceuticals, glucose levels increase, nuclear sclerosis, oxygen toxicity [73-77]. The encircling bands used in the repair of retinal detachments may induce myopia by increasing the axial length of the eye.
 - a. **Index myopia:** It occurs due to the variation in refractive index of the ocular media.
 - b. **Form deprivation:** It occurs when eyesight is hindered in low light or continuous usage of artificial lenses. This type of myopia is reversible.
- vi. **Nearwork-induced transient myopia (NITM):** It can be defined as short-term myopic far point shift immediately following a sustained near visual task [78-83].
- vii. **Instrument myopia:** It occurs due to the continuous usage of an instrument through eyes such as microscope.

On the basis of the degree of severity

1. **Low myopia:** -3.00 diopters or less.
2. **Medium myopia:** Between -3.00 and -6.00 diopters.
3. **High myopia:** Between -6.00 and more.

On the basis of age of onset

1. **Congenital myopia:** This type of myopia occurs in infants during birth and persists till infancy [84-91].
2. **Youth onset myopia:** It occurs in late childhood or teenage and persists till 21 years of age. No surgery is recommended by ophthalmologists [92].
3. **School myopia:** It occurs in school going children who uses their eyes extremely for small purposes.
4. **Adult onset myopia**
5. **Early adult onset myopia:** Age group of 20-40 years.
6. **Late adult onset myopia:** After 40 years.

CONCLUSION AND FUTURE ASPECTS

The condition of Myopia is explained by mismatch theory by many scholars [93-97]. It explains that the human body which had adapted the environment a million years ago was very much different from today's environment. Therefore increase of the non-infectious diseases has occurred such as myopia [98-101].

REFERENCES

1. Agrawal N, Rani N, Haripriya A, Bhuvania P (2014) Outcome of Refractive IOL Exchange in Traumatic Unilateral Axial Myopia. *J Clin Exp Ophthalmol* 5: 385.
2. William YJ (2014) Neurological Implications in the Treatment of Myopia by Means of Orthocology. *J Neurol Neurophysiol* 5: 257.
3. Vinodha R, Shanmugapriya C, Arthy S (2014) Influence of Ocular Dominance on Anisometropic Myopia. *Journal of Medical & Health Sciences*.
4. Sandhya A, Bindu CH, Reddy KP, Vishnupriya S (2011) TGFB1 codon 10 polymorphism and its association with the development of myopia: a case-control study *Biology and Medicine* 3: 18-24 .

5. Sayman Muslubas IB, Cabi C, Aydin Oral AY, Akcay L, Kaplan AT, et al. (2013) Comparison of Outcomes of Posterior Chamber and Iris-Claw Anterior Chamber Phakic Intraocular Lens Implantation for Moderate to High Myopia. *J Clin Exp Ophthalmol* 4: 263.
6. Park JS, Lee SW, Kim SJ, Hong YS (2012) Acute Myopia Induced by Topiramate Plus Phentermine for the Treatment of Obesity. *J Clin Toxicol* 2: 148.
7. Ching-Hua Yeh, Edward Hsi, Suh-Hang Hank Juo (2015) 5th World Congress on Cell & Stem Cell Research, Chicago.
8. Ozkan Onal, Emine Aslanlar, Ali Saltali and Jale Bengi Celik (2014) Anesthetic management in a patient with muscle-eye-brain syndrome. 3rd International Conference on Surgery and Anesthesia, Chicago.
9. Ozkan Onal, Emine Aslanlar, Ali Saltali and Jale Bengi Celik (2014) Anesthetic management in a patient with muscle-eye-brain syndrome. International Conference on HIV/AIDS, STDs, & STIs, Orlando.
10. Aastha Singh (2014) Ophthalmic manifestations in paediatric HIV positive patients in India. International Conference on HIV/AIDS, STDs, & STIs, Orlando.
11. Kenji Yamashiro (2013) Associations of VEGF polymorphisms in choroidal neovascularization secondary to high myopia. 3rd International Conference on Clinical & Experimental Ophthalmology, Chicago.
12. Gopal Bhandari (2013) Ocular morbidity in children with autism. 3rd International Conference on Clinical & Experimental Ophthalmology, Chicago.
13. Mota Á, Fonseca S, Ferreira CS, Faria O, Silva SE, et al. (2013) Retinal Nerve Fiber Layer Thickness Analysis with Optical Coherence Tomography in Wolfram Syndrome. *Int J Ophthalmic Pathol* 2:1.
14. Turgut B, Can N, Demir T, Aydemir O (2013) Double Intraocular Lens: Dislocated One into Vitreous and Implanted One into Posterior Chamber. *Int J Ophthalmic Pathol* 2:1.
15. Durga Devi KB, Sarvamangala D, Narayana Murthy US, Murthy JVS, Vijayalakshmi P (2011) Contact lens infections – a microbiological survey and study. *International Journal of Plant Animal and Environmental Sciences* 78.
16. Venegas L, Hettich M, Villena J, Aris R, Párraga M, et al. (2014) Comparative Analysis of Human Amniotic Membrane Graft versus Contact Lenses in Symptomatic Bullous Keratopathy. *J Stem Cell Res Ther* 4: 250.
17. Pintor J, MartÃ-n-Gil A, Carracedo G, Urbano R, RÃ-os S (2014) Cytotoxic Effect on Corneal Surface of Multipurpose Soft Contact Lens Solution Which Contains Aloe Vera. *Biochem Pharmacol* 3: 128.
18. Baenninger PB, Dinah C, Figueiredo FC (2014) Survey on Bandage Contact Lens Practice in the United Kingdom. *J Clin Exp Ophthalmol* 5: 325.
19. Beglinger KM, Zielewicz L, Wetie AGN, Darie CC (2013) Analysis of Proteins Bound to Contact Lenses. *Mod Chem appl* 1: 114.
20. Phan CM, Hui A, Subbaraman L, Jones L (2014) Insights to Using Contact Lenses for Drug Delivery. *Clin Exp Pharmacol* 4: 145.
21. Ibrahim YW, Boase DL, Cree IA (2012) Incidence of Infectious Corneal Ulcers, Portsmouth Study, UK. *J Clin Experiment Ophthalmol* S6: 001.
22. O'Brart DPS, Ophth FRC, Gavin EA (2011) Contact-Lens Associated Simultaneous Fusarium and Acanthamoeba Keratitis Treated with Therapeutic Penetrating Keratoplasty. *J Clin Experiment Ophthalmol* 2:171.
23. Maka E, Lukáts O, Bausz M, Nagy ZZ, Resch MD (2015) Two Cases of Hallermann-Streiff Syndrome with Retinal Abnormalities. *J Clin Exp Ophthalmol* 6:424.

24. Suwannaraj S, Cavuoto KM, Chang TC (2015) Comparing Structure-Function Correlations in Superior Segmental Optic Nerve Hypoplasia and Juvenile Open Angle Glaucoma Using Spectral-Domain Optical Coherence Tomography. *J Clin Exp Ophthalmol* 6: 413.
25. Maheswari MS, Punnolil A (2014) A Novel Approach for Retinal Lesion Detection In Diabetic Retinopathy Images. *IJRSET* 3: 1109-1114.
26. Rodriguez-Garcia A, Gonzalez-Godinez S, Macias-Rodriguez Y (2015) Amantadine Corneal Toxicity: Case Report and Review of the Literature. *J Ophthalmic Pathol* 4:4.
27. Lin W, Beardsley RM, Skalet AH, Wilson DJ, Rosenbaum JT, et al. (2015) Bilateral Idiopathic Solitary Granuloma of the Uveal Tract: Diagnosis and Treatment. *J Ophthalmic Pathol* 4:4.
28. Qutub MF, Zoroquiain P, Maloney SC, Aldrees SS, Burnier MJr (2015) Toll-Like Receptor 3 is Expressed in All Layers of the Human Sensory Retina and Retinal Pigment Epithelium. *J Ophthalmic Pathol* 4:4.
29. Alamou S, Yehouessi L, Bra'eyatcha Bimingo N, Sounouvou I, Tchabi S, et al.(2015) Epidemiological and Clinical Aspects of Blinding Diseases in The National Teaching Hospital (Cnhu-Hkm) in Cotonou. *J Ophthalmic Pathol* 4:4.
30. Shamsher E, Schutz JS, Thumann G, Chronopoulos A (2015) The Significance of Intraocular Pressure Alterations from Common Therapeutic Interventions: Preliminary Study with Clinical Implications. *J Ophthalmic Pathol* 4:4.
31. Alezzandrini AA, Barberis PCS, Tamaro MA, García MB (2015) Progress And Outcome of Therapeutic Switch to Aflibercept in Patients with Age-Related Macular Degeneration (AMD) Resistant to Bevacizumab. *J Ophthalmic Pathol* 4:4.
32. Landoy and Achiron (2015) Stop Medication to Avoid Oculoplastic Surgery: Prostaglandin-Associated Periorbitopathy. *Int J Ophthalmic Pathol* 4:4
33. Rourke MO, Murphy C (2015) A Description of the Pathological Features of Rheumatoid Corneal Melt Strategies. *J Ophthalmic Pathol* 4:3.
34. Amir H, Salma G, Saloua BA, Amine E, Dorra S (2015) Posterior Scleritis Secondary to Cat Scratch Disease: A Case Report. *J Ophthalmic Pathol* 4:3.
35. Shah N (2015) Letter to Editor : A Case of Choroidal Metastasis Determined to be Hepatocellular Carcinoma. *J Ophthalmic Pathol* 4:3.
36. Alsaati G, Khan N, Deegan W, Sabet S (2015) Metastatic Ductal Breast Carcinoma Mimicking Primary Choroidal Melanoma: A Case Report. *J Ophthalmic Pathol* 4:3.
37. Zain Mehdi, Ahmad AH (2015) Adenoma of the Ciliary Pigment Epithelium Misdiagnosed Clinically as Malignant Melanoma: A Case Report. *Int J Ophthalmic Pathol* 4:2.
38. Bianciardi G, Latronico ME, Traversi C (2015) Decreased Geometric Complexity of Corneal Nerve Fibers Distribution in Sjogren's syndrome Patients. *Int J Ophthalmic Pathol Research* 4:2.
39. Benarous A, Drimbea A, Molva S, Basson W, Gozlan S, et al. (2015) Peripapillary Retinal Nerve Fiber Thickness in Healthy French Children by Spectral-Domain Optical Coherence Tomography. *J Ophthalmic Pathol* 4:2.
40. Shah N, Bhojwani N, Au A, Lee V, Fogt F, et al. (2015) A Case of Choroidal Metastasis Determined to be Hepatocellular Carcinoma . *J Ophthalmic Pathol* 4:2.
41. Savar L, Moscato EE, Kennedy R, Al-Naief S (2015) Adenoid Cystic Carcinoma of the Lacrimal Gland. *Int J Ophthalmic Pathol* 4:1.

42. Priyadarshi SS, Pramod KS, Subhash CP (2015) Diagnosis of Cysticercosis in Eye and Treatment Follow-Up of Extra Ocular Forms by Serum IgGELISA. *Int J Ophthalmic Pathol* 4:1.
43. Amir H, Amine E, Saloua BA, Salma G, Dorra S, et al. (2015) Vitreous Hemorrhage Revealing an Inactive Toxoplasmic Retinochoroiditis: A Case Report. *Int J Ophthalmic Pathol* 4:1.
44. Alwadani F (2015) Waardenburg syndrome (WS) type 1: A Case Report. *Int J Ophthalmic Pathol* 4:1.
45. Arora Y, Bhargava R, Kumar P, Singh D, Gupta P (2016) Unusual Case of an Orbital Lymphangioma Presenting As Chorioretinal Folds with Macular Involvement in an Elderly Patient. *Int J Ophthalmic Pathol* 5:2.
46. Zhu A, Ling Li, Zhong X, Li G, Li Y, et al. (2016) A Clinical Analysis of Age-Related Macular Degeneration in Qinghai Plateau. *Int J Ophthalmic Pathol* 5:2.
47. Chung H, Rasmussen S, Rossman DW (2016) Focal Necrosis in Orbital Pleomorphic Adenoma. *Int J Ophthalmic Pathol* 5:2.
48. Yaghoobi G, Heydari B, Yaghoobi MA, Heydari E (2016) The Review of Behcet Diseases: A Case of Sub-acute Bilateral Hypopyonic Uveitis after 20 Years of Behcet Diseases. *Int J Ophthalmic Pathol* 5:2.
49. Gupta S, Sharma RK, Tuli R (2016) Evaluation for Dry Eye and Intra Ocular Pressure in Patients on Antihypertensive Medications. *Int J Ophthalmic Pathol* 5:2.
50. Assavedo CRA, Alamou S, Yehouesi L, Ayedoun KR, Salifou K, et al. (2016) Hypertensive Retinopathy during Pregnancy: Epidemiological and Clinical Aspects at Departmental University Center of Borgou. *Int J Ophthalmic Pathol* 5:1.
51. Bypareddy R, Sen S, Chawla R (2016) In-Toto Removal of Sub-Retinal Cysticercosis and its Histopathology. *Int J Ophthalmic Pathol* 5:1.
52. Sharma OP, Deepak M (2016) B-Scan Dynamic Sonographic Studies in Orbital Pathologies. *Int J Ophthalmic Pathol* 5:1.
53. Laayoun J, Elmellaoui M, Bouzidi A, Zawi K, Iferkhas S, et al. (2016) Acute Myeloid Leukemia Revealed by Abducens Nerve Palsy: About One Case. *Int J Ophthalmic Pathol* 5:1.
54. Kiziltunc PB, Atilla H, Akbostanci C, Isikay CT, Ataoglu O (2016) Lacrimal Gland Metastasis and Paraneoplastic Orbital Myositis due to Breast Carcinoma. *Int J Ophthalmic Pathol* 5:1.
55. Chebbi A, Ben Romdhane O, Hachicha F, Bouzaeine M, Bouayed E, et al. (2014) Diagnostic and Therapeutic Approach of the Malignant Choroidal Melanoma in a 12-Year-Old Child. *J Ophthalmic Pathol* 3:4.
56. Bhargava R and Kumar P (2014) Conjunctival Impression Cytology in Computer Users. *J Ophthalmic Pathol* 3:4.
57. Kayabasi U, Sergott RC Rispoli M (2014) Retinal Examination for the Diagnosis of Alzheimer's Disease. *J Ophthalmic Pathol* 3:4.
58. NG (2014) Aspiration Cytology in Ciliary Body Medulloepithelioma. *J Ophthalmic Pathol* 3:4.
59. Bhargava R (2014) A Review of Posterior Capsule Opacification. *J Ophthalmic Pathol* 3:4.
60. Song S, Shi ZA, Dai H, Xiao-bing Yu (2014) Unilateral Posterior Scleritis and Exudative Retinal Detachment Complicating a Single Zoledronate Infusion for Osteoporosis. *J Ophthalmic Pathol* 3:4.
61. Song S, Shi ZA, Dai H, Xiao-bing Yu (2014) Unilateral Posterior Scleritis and Exudative Retinal Detachment Complicating a Single Zoledronate Infusion for Osteoporosis. *J Ophthalmic Pathol* 3:4.

62. Malik MA, Shabbir N, Saeed M, Malik H (2014) Evaluation of Factors Influencing Medication Adherence in Children with Epilepsy in Under- Resource Community at Bhakhar City of South-Punjab, Pakistan. *J Ophthalmic Pathol* 3:5.
63. Mishra A, Kabra R, Kashif MAW Srinivasan B (2014) Conjunctival Growth Extending onto the Cornea? Think Beyond Just A Pterygium!. *J Ophthalmic Pathol* 3:4.
64. Chen S, Malik KJ, Shen D, Chan CC (2014) Acute Retinal Necrosis with Multiple Viral Infections: A Case Report. *J Ophthalmic Pathol* 3:5.
65. Perry AR, Huie P, He L, Milman T, Ta1 CN (2014) India Ink Infiltration in Scleral Wounds After Intravitreal Injections. *J Ophthalmic Pathol* 3:4.
66. Assavedo CRA, Alamou S, Yehouesi L, Ayedoun KR, Salifou K, et al. (2016) Hypertensive Retinopathy during Pregnancy: Epidemiological and Clinical Aspects at Departmental University Center of Borgou. *Int J Ophthalmic Pathol* 5:1.
67. Bypareddy R, Sen S, Chawla R (2016) In-Toto Removal of Sub-Retinal Cysticercosis and its Histopathology. *Int J Ophthalmic Pathol* 5:1.
68. Sharma OP, Deepak M (2016) B-Scan Dynamic Sonographic Studies in Orbital Pathologies. *Int J Ophthalmic Pathol* 5:1.
69. Laayoun J, Elmellaoui M, Bouzidi A, Zawi K, Iferkhas S, et al. (2016) Acute Myeloid Leukemia Revealed by Abducens Nerve Palsy: About One Case. *Int J Ophthalmic Pathol* 5:1.
70. Kiziltunc PB, Atilla H, Akbostanci C, Isikay CT, Ataoglu O (2016) Lacrimal Gland Metastasis and Paraneoplastic Orbital Myositis due to Breast Carcinoma. *Int J Ophthalmic Pathol* 5:1. doi:10.4172/2324-8599.
71. Chen M and Phelps PO (2014) A Case Report: Extranodal Marginal Zone Lymphoma of the Eyelid. *Int J Ophthalmic Pathol* 3:1.
72. Lee D, Santana SG, Huang JJ (2014) Silicone Rubber Scleral Buckle Implant Simulating Conjunctival Tumor. *Int J Ophthalmic Pathol* 3:1.
73. Deepak Mishra (2014) Congenital Orbital Teratoma: A Rare Presentation . *Int J Ophthalmic Pathol* 3:1.
74. Hachicha F, Cheour M, Lajmi H, Ouederni M, Brour J (2014) Exophthalmia as a First Manifestation of Epithelioid Hemangioma. *Int J Ophthalmic Pathol* 3:1.
75. Fatani HA, Junco GD, Murugan P, El-Naggar AK (2014) Ocular Non-pigmented Ciliary Adenomatous Neoplasm: Report of a Rare Case and Review of the Clinicopathologic Classification. *Int J Ophthalmic Pathol* 3:1.
76. Hachicha F, Ben Abdesslem N, Lajmi H, Ouederni M, Brour J et al.,(2014) A Rare and Incomplete Form of Sturge Weber Syndrome: Glaucoma without Choroidal Hemangioma nor Neurologic Manifestations. *Int J Ophthalmic Pathol* 3:2.
77. Ooi ILE , Umi Kalthum MN, Suzaily W , Aida Zairani MZ, Yong TK (2014) Ocular Manifestation of Chlorpromazine Toxicity- A Case Report. *J Ophthalmic Pathol* 3:2.
78. Ergen I, Kobat SG, Turgut B, Çatak O (2014) Multimodal Imaging in Two Cases with Choroidal Osteoma. *J Ophthalmic Pathol* 3:2.
79. Chebbi A, Lajmi H, Abbes I, Malek I, Zeghal I, et al. (2014) Conjunctival Kaposi Sarcoma Revealing HIV Infection. *J Ophthalmic Pathol* 3:2.

80. Ali YM, Elahe H, Gholamhossein Y (2014) Unilateral Chorioretinal Finding: A Presumptive Diagnosis in a Case of 5 Years Ago Treatment of Extrapulmonary Tuberculosis. *J Ophthalmic Pathol* 3:2.
81. Chebbi A, Zeghal I, Ouederni M, Lajmi H, Jablaoui Y, et al. (2014) Intraorbital Foreign Body: The Hidden Side of the Iceberg. *J Ophthalmic Pathol* 3:2.
82. Turgut B, Tanyildizi R (2013) The Frequency of the Nonresponsiveness to Intravitreal Injection of the Anti-Vascular Endothelial Growth Factor Agent in Neovascular Age Related Macular Degeneration. *Int J Ophthalmic Pathol* 2:3.
83. Demir M, Oba E, Ozdal E, Sensoz H (2013) Intraocular Pressure after Triamcinolone Acetonide Assisted Anterior Vitrectomy in Patients who Underwent Complicated Cataract Surgery. *Int J Ophthalmic Pathol* 2:4.
84. Bansal S (2013) Traumatic Chiasmal Syndrome - A Case Report. *Int J Ophthalmic Pathol* 2:4.
85. Rizvi SAR, Kesarwani D, Maheshwari V, Aziz M (2013) Eyelid Plexiform Neurofibroma: Atypical Presentation and Management. *Int J Ophthalmic Pathol* 2:4.
86. Balarabe AH, Ayanniyi AA, Monsudi KF (2013) Challenges of Managing Advanced Retinoblastoma in a 4 Year Old Nigerian Girl: Case Report and Review of Literature. *Int J Ophthalmic Pathol* 2:4.
87. Omolase CO, Adedosu AN, Omolase BO, Sotiloye OA, Omolade EO, et al. (2013) Ocular Loiasis in a Nigerian Female Adult. *Int J Ophthalmic Pathol* 2:4.
88. Hwang JC, Khine KT, Rao NA, Minckler DS, Memarzadeh F, et al. (2013) Assessment of the Anterior Chamber Angle after Trabectome Glaucoma Surgery by Optical Coherence Tomography, Histopathology, Ultrasound Biomicroscopy, and Scanning Electron Microscopy. *Int J Ophthalmic Pathol* 2:4.
89. Bağkesen H, Uysal Y, Ulaş ÜH, Dağlı O (2013) Papilledema as the Presenting Manifestation of Neurobrucellosis. *Int J Ophthalmic Pathol* 2:4.
90. Sgrignoli MR, Yamasaki L, de Carvalho Sanches O, Giuffrida R, Ricci CL, et al. (2013) Comparison of Topical 0.03% Tacrolimus in Almond and Linseed Oil to Treat Experimentally Induced Keratoconjunctivitis Sicca in Rabbits. *Int J Ophthalmic Pathol* 2:3.
91. Verdijk RM (2013) Extramedullary Hematopoiesis in Abusive Head Trauma. *Int J Ophthalmic Pathol* 2:3.
92. Ng JS, Chin T, Vydellingum M, Yacoub R, Guenther C (2013) Detection of Diabetic Retinal Neuropathy Using Standard Clinical Electrodiagnostic Testing. *Int J Ophthalmic Pathol* 2:3.
93. Turgut B, Arslan S, Gul FC, Çatak O (2013) Recurrent Pterygium with Cilia Mimicking Ectopic Cilia. *Int J Ophthalmic Pathol* 2:3.
94. Alhabshan R, Belyea D, Stepp MA, Barratt J, Grewal S, et al. (2013) Effects of In-vivo Application of Cold Atmospheric Plasma on Corneal Wound Healing in New Zealand White Rabbits. *Int J Ophthalmic Pathol* 2:3.
95. Oleksyszyn J (2012) Hyperglycemia and Tumor Energy Metabolism. *J Pharmacol Biomed Anal* 1:1.
96. Malik M, Hassali MA, Shafie AA, Hussain A, Aljadhey H (2012) Availability of Different Strengths of Anti Malarial Preparations in Pakistan: Implication for Patient Safety. *J Pharmacol Biomed Anal* 1:1.
97. Lawania RD, Mishra A (2013) Anticancer Potential of Plants and Natural Products: A Review. *J Pharmacol Biomed Anal* 1:2.
98. Bamisaye FA, Oloyede OB, Yakubu MT (2013) Effects of Aqueous Extract of *Phyllanthus muellerianus* Leaves on Castor Oil-induced Diarrhoeal Rats. *J Pharmacol Biomed Anal* 1:2.
99. Mei Y, Thompson MD, Cohen RA, Tong XY (2013) Endoplasmic Reticulum Stress and Related Pathological Processes. *J Pharmacol Biomed Anal* 1:2.

100. Horng H, Benet LZ (2013) The Effects of 1-Aminobenzotriazole Inhibition on the Formation of Acyl-Glucuronide and Acyl-Glutathione Metabolites in Rat Hepatocytes. J Diagn Tech Biomed Anal 2:1.
101. Ghareeb DA, Sarhan EME (2014) Role of Oxidative Stress in Male Fertility and Idiopathic Infertility: Causes and Treatment. J Diagn Tech Biomed Anal 2:1.