

Morphological Study of External Ear in Mentally Retarded and Healthy Subjects.

Dashrath Haribhau Pimple, Geetha KN*, Karuna N Katti, and GV Kesari.

MGM Medical College, MGM Institute of Health Sciences, Navi Mumai, Maharashtra, India.

Research Article

Received: 19/09/2013
Revised: 25/09/2013
Accepted: 03/10/2013

*For Correspondence

MGM Medical College, MGM
Institute of Health Sciences,
Navi Mumai, Maharashtra, India.

Keywords: Morphology, external ear, congenital anomalies, syndromes

ABSTRACT

The external ear is a unique part of the human sensory system. Morphological defects of external ear are important because of the associated syndromes and conditions. 50% of the malformations of the ENT involve the ear. Ear malformations may be genetic (associated with syndromes or spontaneous mutations) or acquired in nature. The present study is undertaken to analyse the morphological features of external ear in normal and in subjects with mental retardation of various origin. The study was conducted in 100 subjects out of the same 50 were normal first year medical students and 50 were students with mental retardation from a school for special children. Parameters selected were the morphological features of external ear like presence or absence of Helix, Tragus, Antitragus, overall shape of the ear, features of lobule etc. 90% of the mentally retarded group showed bilateral differences in morphological features of external ear whereas only 2% of the normal healthy subjects showed bilateral differences. Positive correlation was observed between mental retardation of various etiology and morphological anomalies of the external ear.

INTRODUCTION

The human ear is a defining feature of the face. Ears play a vital role in producing a natural and harmonious look and an aesthetically fine facial appearance. Congenital defects of the auricle result from disruption of complex developmental events and may lead to many combinations of both external and middle ear disorders. Morphological defects of external ear are important because of the associated syndromes and conditions. 50% of the malformation of the ENT involves the ear. Malformations of the outer and middle ear are predominantly unilateral. Incidence of ear malformation is 1 in 3800 new born and that of external ear is 1 in 6000 new born. Ear pits and tags are the most common minor ear malformations occur with a frequency of 5 - 6 in 1000 live births. Ear malformation may be genetic (associated with syndromes or not, with family history, spontaneous mutations) or acquired in nature. About 30 % of congenital malformations are associated with syndromes involving additional malformation and / or functional loss of organs or organ systems. Example:- oto facial dystosis (eg. Crouzon syndrome, Apert syndrome), chromosomal syndroms (eg. Patau, Edward and Down syndrome). The non syndromal ear malformation show only anomalies of the ear without any other malformations. An acquired ear malformation originate from exogenic injury during pregnancy i.e. viral infections like TORCH, herpes simplex, chicken pox etc, chemical agents - Alcohol drugs like thalidomide, quinine, anti convulsants etc, malnutrition, vitamin A deficiency, hypoxia, radiation, Rh incompatibility, diabetes etc.

The auricle develops from six mesenchymal proliferations around the first branchial cleft. The mesenchymal proliferations / hillocks which develop from first branchial (mandibular) arch give rise to 1, 2 & 3 hillocks and the second branchial (hyoid) arch give rise to 4, 5 & 6 hillocks. Arrested development or failure of differentiation of parts of the auricular primodium can result in various types of malformation of the external ear with differing degrees of severity. The classification of the auricular malformation shows increasing grades with increasing severity of the malformations.

Grade I dysplasia: slight malformation. Most structure of the normal pinna is recognizable.

Grade II dysplasia: moderate malformation. Also termed microtia grade II, some structure of a normal auricle are recognizable.

Grade III dysplasia: severe malformation. Also termed as microtia grade III. None of the normal structure of the pinna are recognizable

According to Tanze:-

Type I – slight deformity - Affects only the helix. Cup shaped projection of the helix over the scapha.

Type II deformity, the helix and anti helix with its crura and the scapha are affected.

Type III – severe deformity. Marked underdevelopment of the upper pinna, often dystopia and anterior positioning and external auditory canal stenosis ^[1]

Morphological defects of the external ear represent a significant class of congenital abnormalities because of their overall frequency of associated syndromes, involvement of other organs like kidney and their psychological impact on affected people.

The present study is undertaken to analyse the morphological features of external ear in normal and in subjects with mental retardation of various origin ^[2,3,4,5].

MATERIALS AND METHODS

The present study was conducted in MGM Medical College and Swami Bhramhanand Pratishtan Disha Special School CBD Belapur, Navi Mumbai.

A total number of 100 subjects were considered for the study, prior informed consent was taken from the institution authorities. Subjects were briefed about the procedure for full co-operation. Inclusion criteria were the documented history of mental retardation and related disorder from the institution admission records.

Parameters or traits considered for the study are the following

Helix – its presence or absence

Tragus – its presence or absence

Anti tragus – its presence or absence

Overall size of the auricle- large or small

Shape of the ear – lop or cup shaped

Lobule – adherent or cleft etc

Method

For each subject the auricle of both sides were analyzed for any morphological abnormalities.

After confirmation of the anomaly photographs of both left and right auricle were taken along with their tag number for future identification. The related disorder was retrieved from the institution documents.

Table No 1: Morphological changes of the auricle.

Sr. No.	Tag No.	Side	Morphological changes	Causes for Mental retardation
1	4	Left	Inverted helix, Prominent antitragus	Delayed development
2	21	Right Left	Cup shaped, Inverted wide helix, prominent anti tragus Small lobule	Down's syndrome
3	23	Right Left	Inverted helix, Small lobule Lop ear	Delayed development
4	26	Right	Short crus of helix, Large concha completely covered with tragus	Cerebral palsy
5	50	Left	Thin cartilage of helix Wide inter tragic notch	Down's syndrome
6	63	Right Left	Misshaped ear, Adherent lobule, Scaphoid fossa incomplete distally Microtia, Small lobule	Down's syndrome
7	68	Right Left	Small lobule, Small tragus, Darwinian tubercle Large concha, Broad helix, Small lobule	Other
8	74	Left Right	Normal Small lobule	Autism
9	76	Left Right	Inverted helix Inverted helix, Short crus, Microtia, Small tragus shifted distally	Down's syndrome
10	77	Left	Small lobule, Intertragic noych wide.	Fragile X syndrome
11	79	Right Left Right	Cup shaped ear Cup shaped ear Cup shaped ear	Down's syndrome
12	84	Left	Small lobule	Down's Syndrome
13	88	Right Left	Microtia, Lobule absent, Small tragus Inverted helix, Deep scaphoid and triangular fossa, Adherent lobule	Autism
14	92	Right Left	Crus of helix shifted distally so wide symba Concha, Lobule absent Small lobule	Down's Syndrome
15	98	Right Left	Normal Antihelix covering concha, antitragus covering concha	Delayed Development

RESULTS

All subject with mental retardation showed one or more malformation.

All subject with Down syndrome contrary to the report that they are associated with small but normal ear morphology, this study showed various malformations including microtia, lobule variation etc.

In subjects with mental retardation 54% showed varying degrees of ear anomalies.

Out of 50 subject with mental retardation 14 (28%) were associated with specific syndrome. All of them had specific structural known ear anomalies.

60% of the non syndromic subject with mental retardation (30 out 50) showed no specific ear anomalies. In normal sample the anomalies were rare. Only 1subject showed absence of tragus.

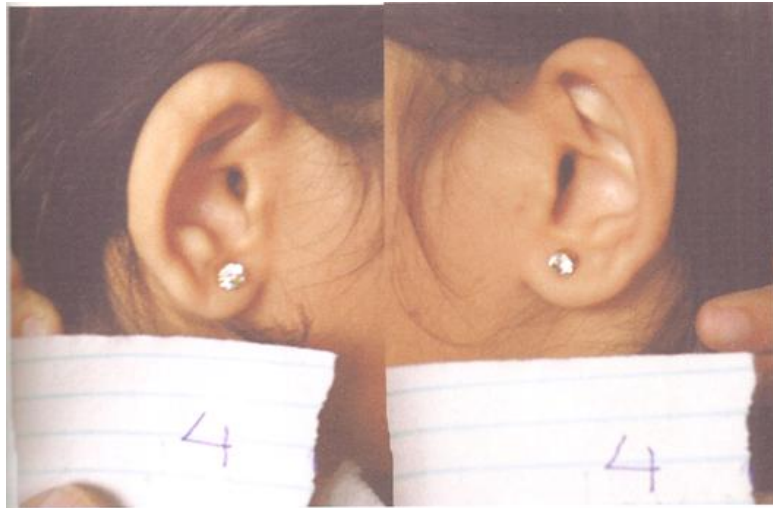


Figure 1: Right: Cup shaped, Inverted wide helix, prominent anti tragus
Left: Inverted wide helix, Prominent antitragus

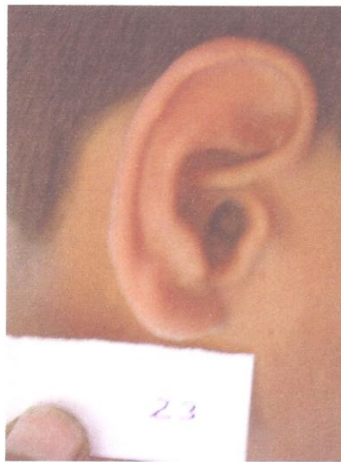


Figure 2: Left: Lop ear; Right: Short crus of helix, Large concha completely covered with tragus

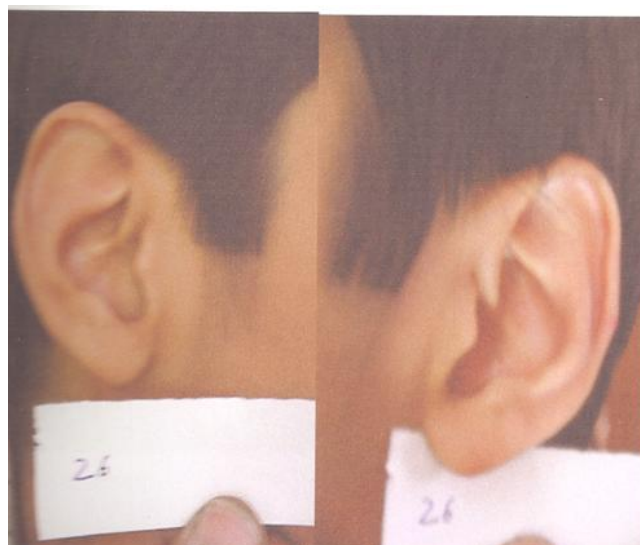

Figure 3: Right and Left: Wide inter tragic notch , Thin cartilage of helix

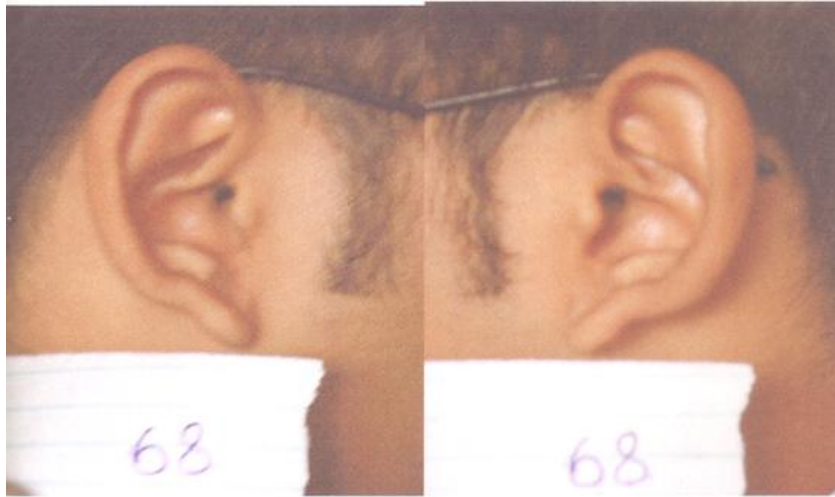

Figure 4: Right: Small tragus, External acoustic meatus is small, Turned lobule
Left: : Small tragus, Turned lobule

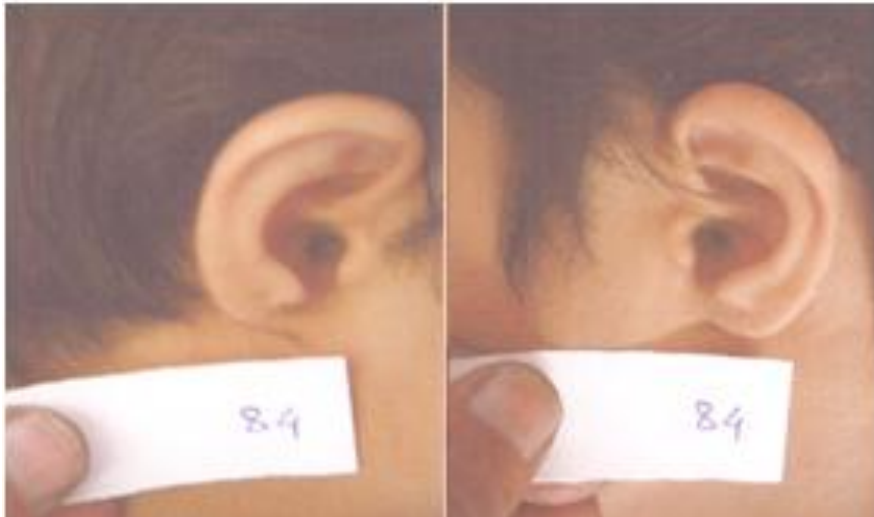

Figure 5: Right: Microtia, Lobule absent, Small tragus, Left: Small lobule

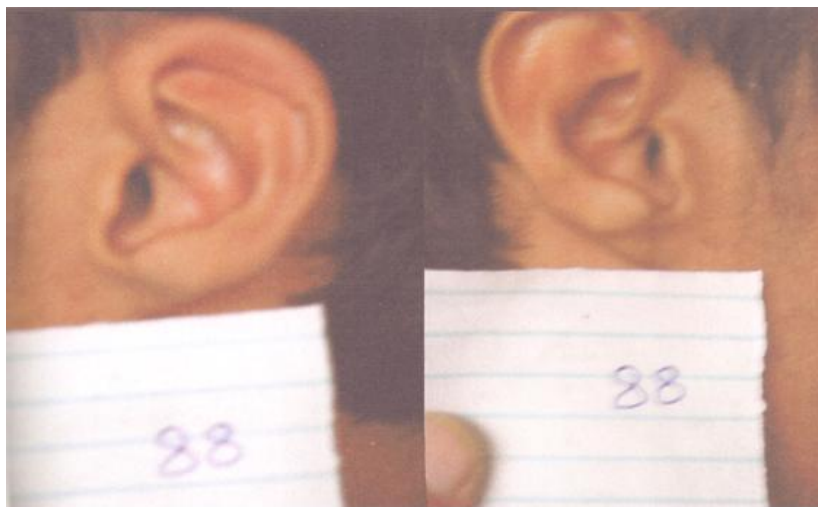


Fig 6: Right: Concha, Lobule absent
Left: Inverted helix, Deep scaphoid and triangular fossa, Adherent lobule, Crus of helix shifted distally so wide symba

DISCUSSION

The ear is a defining feature of the face. The present study was undertaken to evaluate and understand auricular development in mentally retarded subjects. For this study we randomly selected 50 mentally retarded subjects and 50 normal subjects. We also studied morphometry of the auricle to analyse any morphological abnormalities.

Definitive morphological changes are associated with mentally retarded subjects which are shown in table number 2 in observation.

Table no.2: The incidence of morphological abnormalities in mentally retarded group is as follows.

Sr.No.	Morphological Abnormality	Incidence in %
1	Microtia	6%
2	Inverted Helix	16%
3	Prominent Tragus	12%
4	Prominent Antitragus	6%
5	Adherent Lobule	22%
6	Lop Ear	8%
7	Other(cup shaped ear, wide helix/ inverted helix, small lobule, short crus of helix, large conchae, thin helix, wide intertragic notch, small tragus, lobule absent / attached, anti helix covering conchae, Darwinian tubercle, turned lobule/absent lobule)	44%

Almost all these abnormalities are seen in Down's syndrome, out of seven cases almost 5 showed some or other morphological abnormalities of external ear.

In control group only 1 subject showed absence of tragus, which is hardly 2% while in others the morphology of auricle was normal.

In our study 49 out of 50 mentally retarded subjects showed bilateral differences i.e. 98%. In control group only 1 out of 50 showed bilateral differences i.e. 2%. This is small scale study, just to see the relationship between mental retardation and morphological abnormalities of the auricle. To comment authoritatively we need a large scale study [6,7,8].

CONCLUSION

The ear is an important feature of the face. Morphology of the auricle is neglected, though the malformation of auricle is associated with many congenital disorders and syndromes. We conducted this study of morphology of auricle in 50 mentally retarded subjects and 50 healthy subjects without mental retardation. Positive correlation was observed between mental retardation of various etiology and morphological anomalies of the external ear. Association was found in 72% cases, only 2% of normal subjects showed bilateral differences. Large scale study will help to find out further correlation and its significance.

REFERENCES

1. Anupama Patil MD, Malformation of external ear, The fetus. Net 2001-01-02 page 1-14
2. Alasdair G W Hunter, Takatoshi Yotsuyangi, The external ear – more attention to detail may aid syndrome diagnosis and contribute answers to questions. American J Med Genet A. 2005;135 (3): 237-250.
3. A Sulaiman , H Nawaz, I Munaiat, A Sallehudin, Proximal femoral focal deficiency as a manifestation of Antley-Bixler syndrome: a case report. J Orthop-Surgery (Hong Kong). 2007;15(1): 84-86.
4. Abraham Shulman, Arnold M Strashun, Barbra Goldstein, Martin Lenhardt, Congenital atresia of external ear and tinnitus: A New syndrome. Internal Tinnitus J. 2006 ;12(1): 17-30.
5. A Marcolla, P Bouchetemple, Y Lerosey, J P Marie, D Dehesdin Genetic deafness Ann Otolaryngol – Chir Cervicofac. 2006;123(3):143-7.
6. C Sforza, C Dellavia, G M Tartaglia and V F Ferrario. Morphometry of the ear in downs syndrome subject: A three dimensional computerized assessment Mangiagalli 31, 1-20133 Milano Italy. Int J Oral Maxillofacial Surg. 2005;34:480-486.
7. Cagatay Barut & Erol Aktunc. Anthropometric measurement of the external ear in a group of Turkish primary school students. Published online : 17 March 2006
8. D Lucke, C Stroszczyński, S Gartenschlager, H Olze, Otologic finding in the Apert syndrome. Laryngo-rhinotologic. 2006;85(5): 344-7.