

# Research & Reviews: Journal of Pharmacognosy and Phytochemistry

## Evaluation of the hepatoprotective activity of *Fagonia cretica* L

Hala Salah Eldin, Haidar Abdal Gadir\*, Abdel Wahab Hassan

Medicinal and Aromatic Plants Research Institute (MAPRI), National center for Research, Khartoum, Sudan.

### Research Article

Received date: 17/06/2015

Accepted date: 02/09/2015

Published date: 12/09/2015

#### \*For Correspondence

Dr. Haidar Abd Algadir, Plant Taxonomist,  
Herbarium Curator, Medicinal and  
Aromatic Plants Research Institute  
National Research Center, Khartoum,  
Sudan, Tel: +249-912821892

E-mail: haidar222@gmail.com

Keywords: *Fagonia cretica*,  
Hepatoprotective, Histopathological,  
Silymarin

#### ABSTRACT

*Fagonia cretica* L. (Zygophyllaceae) herb is widely distributed in Sudan and used in Sudanese traditional medicine for the treatment of various disorders. The present study was designed to assess the hepatoprotective activity and cytotoxicity of methanolic and water extracts of *F. cretica* L. These extracts were studied for their hepatoprotective activity using CCl<sub>4</sub> induced liver damage in wistar albino rats. The methanolic and water extracts of *F. cretica* L. at oral dose of (400 mg/kg) showed highly significant ( $p < 0.01$ ) hepatoprotective effect. These biochemical observations were confirmed by histopathological examinations of liver sections comparable with the standard hepatoprotective drug Silymarin (100 mg/kg) which served as a positive control.

### INTRODUCTION

Traditional medicine has a long history. It is the sum of knowledge, skill, and practices based on the theories, beliefs, and experience indigenous to different cultures, used in the maintenance of health as well as in the prevention<sup>[1]</sup>. Sudan is one of the largest countries in Africa with a diverse flora. Most of Sudanese people in rural areas rely on traditional medicine for the treatment of many infectious diseases. Sudanese traditional medicine is a unique combination of knowledge and practices of Arabic, Islamic and African cultures<sup>[2,3]</sup>. Medicinal plants have a promising future because there are about half million plants around the world, and most of their medical benefits have not been investigated yet, and their medical activities could be decisive in the treatment of present or future studies<sup>[4]</sup>. More than 80% of the world population in developing countries uses plant derived medicines and about half of the population in industrialized countries also are using traditional medicines practices to meet their healthcare needs<sup>[5,6]</sup>. In Sudan, people dependant on medicinal plants for health care is estimated at over 90% of the population, these plants and derived products play an important role in the primary health care of Sudan<sup>[7]</sup>.

Liver is vital organ that play a major role in metabolism, energy production and bile production, storage of iron, vitamins and trace elements, detoxification and conversion of waste products for excretion by the kidneys<sup>[8]</sup>. Liver injury or liver dysfunction is a major health problem that challenges not only health care professionals but also the pharmaceutical industry and drug regulatory agencies. Liver cell injury caused by various toxicants (certain anti-biotic, chemotherapeutic agents, carbon tetrachloride (CCL<sub>4</sub>), thioacetamide (TAA) etc.), D-galactosamine, Paracetamol, excessive alcohol consumption and microbes<sup>[9,10]</sup>. A large number of plants and formulations have been claimed to posses hepatoprotective activity.

#### ***Fagonia cretica* L.**

Is a small spiny under shrub mostly found in dry calcareous rocks, belongs to family Zygophyllaceae<sup>[11]</sup>, It is locally known as (Shokat algemal, Umm Shawaika and Al agoul), and found in the West, Northern and Central Sudan<sup>[12]</sup> (**Figure 1**).



**Figure 1:** *Fagonia cretica* L.

In traditional medicine, *Fagonia cretica* L. is used as astringent, febrifuge, liver trouble and prophylactic against small-pox. An aqueous decoction of the plant is used to induce abortion, a popular remedy for cancer in the indigenous system of medicine [13] and in the treatment of snake bite [14].

*Fagonia cretica* L. exhibited antimicrobial activity against bacterial strains [11]. It also reported that the plant aqueous extract has an anti breast cancer effect without exhibiting common side effects of standard cytotoxic therapy [15]. The methanolic extract possesses potentials as haemorrhagic inhibitor against snake venom compared to the standard antiserum [14]. Antitumor, antioxidant activities were also reported [16].

## MATERIAL AND METHODS

### Plant Materials

The Plant materials were collected from their natural habitat from different localities in Sudan. Plants were taxonomically identified and authenticated by Dr. Haidar Abd Algardir at the Herbarium of Medicinal and Aromatic Plants and Traditional Medicine Research Institute, where the voucher specimens have been deposited for future references.

### Preparation of plant extracts

The shade dried materials were ground, powdered and divided into two portions. One portion was extracted with 100% methanol at room temperature, and then the obtained residue was evaporated to dryness using rotatory evaporator to afford methanolic extracts. Whereas, other portion of the powdered material was extracted using boiling water then filtered, the obtained filtrate was dried using a freeze dryer to afford aqueous extract or water extract.

### Phytochemical screening

Phytochemical screening of the studied extracts gives information about the nature of the constituents found in the plants. (Tannins, Triterpenes, Alkaloids, Flavonoids, Saponins, Coumarins and Anthraquinone glycosides).

### Assessment of hepatoprotective activity

Methanolic and water extracts of *Fagonia cretica* L. were evaluated for their hepatoprotective activity. Wistar albino rats weighing 90-100 g of either sex maintained under standard husbandry conditions (temp  $23 \pm 2^\circ\text{C}$ , relative humidity  $55 \pm 10\%$  and 12 hours light dark cycle) were used for the screening (as models). Animals were fed with standard laboratory food and ad libitum during the study period. Rats were divided into seven groups of five animals each, for each extract. Normal control rats (group I) received three doses of 5% gum acacia mucilage (1 ml/kg) orally at 12 hours intervals (0 hour, 12 hours and 24 hours) negative control rats (group II) received three doses of vehicle at 12 hours intervals and a single dose of Carbon tetrachloride (1.25 ml/kg i.p.) diluted in liquid paraffin (1:1) subcutaneous injection. 30 minutes after the administration of first dose of vehicle, rats of standard (group III) received three doses of Silymarin, (100 mg/kg) at 0 hour, 12 hours and 24 hours. Carbon tetrachloride was administered (1.25 ml/kg i.p.) 30 minutes before the first dose of Silymarin which represents positive control. On the other hand, rats of test (group IV), and (V), received two doses of methanolic extracts 200 and 400 mg/kg body weight, while (group VI), (VII) received two doses of water extracts at dose of 200 and 400 mg/kg body weight respectively at 0 hour, 12 hours and 24 hours. Carbon tetrachloride was administered (1.25 ml/kg i.p.) 30 minutes before the first dose of test extracts [17], after 36 hours of administration of Carbon tetrachloride, animals were sacrificed and blood sample for Hematological and Biochemical Analysis were collected into test tubes with and without EDTA, respectively. Hemoglobin (HB), Haematocrit (HCT), Red Blood Cell count (RBC), White Blood Cell count (WBC), Mean Corpuscular Hemoglobin Concentration (MCHC), Mean Corpuscular Hemoglobin (MCH), Mean Corpuscular Volume (MCV) and Platelet Count were determined using Hematology Analyser (Humacount Plus, Germany). Biochemical analysis was performed on serum obtained after centrifugation of total blood (without anticoagulant) at 2500 rpm for 15 min. automated system (COBAS Plus Integra 400, Germany) was used for determination of the biochemical parameters (Alanine Aminotransferase (ALT), Aspartate Aminotransferase (AST), Creatinine, Alkaline Phosphatase (ALP), Bilirubin, Albumin, Total Protein, Urea, Creatinine, and Cholesterol).

## Histopathological Study

Liver sample from each rat were removed after dissection and preserved in 10% formalin. Using the standard micro technique [18]. Sections were taken at (5 μm) thickness and stained with hemotoxylin and eosin dye, the sections were then observed under microscope for histopathological changes in liver architecture, and their photomicrographs were taken using micro imaging microscope (Olympus BX 51, Japan).

## Statistical Analysis

Statistical Package for Social Science (SPSS) was used for the analysis of the data. The significance of differences between means was compared among the groups using Independent-sample T-test. For brine shrimp test data was analyzed with Finney computer program to determine LD50 values with 95% confidence intervals.

# RESULTS

## Phytochemical Screening

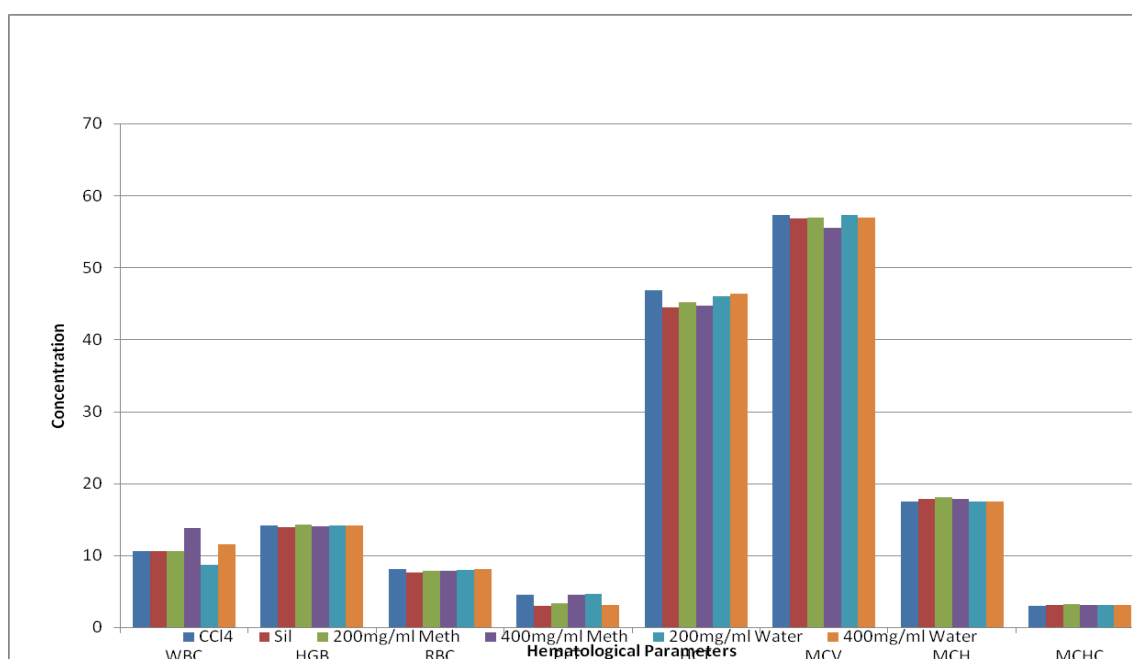
Phytochemical screening was performed for the extracts of the studied plant. In the present study, water extracts of *Fagonia cretica* L. revealed presence of high content of saponin compared to the methanolic extracts, same content of flavonoids. Tannins, coumarin and triterpens were also detected.

## Hematological Parameters

There were no significant changes in the hematological parameters of both methanolic and water extracts of *Fagonia cretica* L. compared to Silymarin and CCl<sub>4</sub> treated groups of rats. These results were shown in **Table 1 and Figure 2**.

**Table 1.** Effect of methanolic and water extracts of *Fagonia cretica* L on hematological parameters.

Hematological Parameters	Normal Control	CCl <sub>4</sub>	Silymarin	Methanolic extract		Water extract	
				200 mg/ml	400 mg/ml	200 mg/ml	400 mg/ml
WBC (×10 <sup>9</sup> /L)	14.38 ± 0.97	10.60 ± 3.05	10.62 ± 1.81	10.62 ± 1.22	13.84 ± 0.60	8.62 ± 0.44	11.52 ± 0.56
HGB (g/dl)	14.50 ± 0.96	14.20 ± 0.17	13.90 ± .24	14.30 ± 0.38	14.06 ± 0.01	14.20 ± 0.298	14.18 ± 0.17
RBC (×10 <sup>12</sup> /L)	9.16 ± 0.50	8.08 ± 0.47	7.56 ± 0.38	7.90 ± 0.74	7.86 ± 0.23	7.96 ± 0.40	8.1 ± 0.15
PLT (×10 <sup>9</sup> /L)	1.89 ± 2.65	4.47 ± 51.10	2.96 ± 167.9	3.38 ± 136.4	4.52 ± 86.50	4.64 ± 161.07	3.14 ± 120.07
HCT(%)	51.80 ± 1.97	46.86 ± 0.94	44.40 ± 0.80	45.18 ± 1.67	44.64 ± 0.49	46.02 ± 1.20	46.34 ± 0.59
MCV(fl)	55.00 ± 0.94	57.30 ± 0.67	56.80 ± 0.32	56.94 ± 0.57	55.46 ± 0.55	57.30 ± 0.52	56.98 ± 0.43
MCH(pg)	15.16 ± 0.16	17.44 ± 0.29	17.82 ± 0.08	18.06 ± 0.33	17.78 ± 0.26	17.44 ± 8	17.44 ± 0.26
MCHC (g/dL)	2.71 ± 6.25	3.01 ± 2.57	3.11 ± 3.34	3.16 ± 3.71	3.13 ± 5.9	3.07 ± 3.20	3.05 ± 4.50



**Figure 2.** Effect of methanolic and water extracts of *Fagonia cretica* L on Hematological Parameters

## Biochemical Parameters of *Fagonia cretica* L.

At dose of 400 mg/ml methanolic extract represented highly significant changes ( $P < 0.01$ ) on the enzyme levels alanine aminotransferase (ALT), aspartate aminotransferase (AST) and alkaline phosphotase (ALP) compared to Silymarin and  $CCl_4$  treated groups of rats.

The methanolic and water extracts of *Fagonia cretica* L. exhibited remarkable effect in lowering the high level of liver enzymes that elevated by  $CCl_4$  induced cell damage. These results were shown in **Table 2** and **Figure 3**.

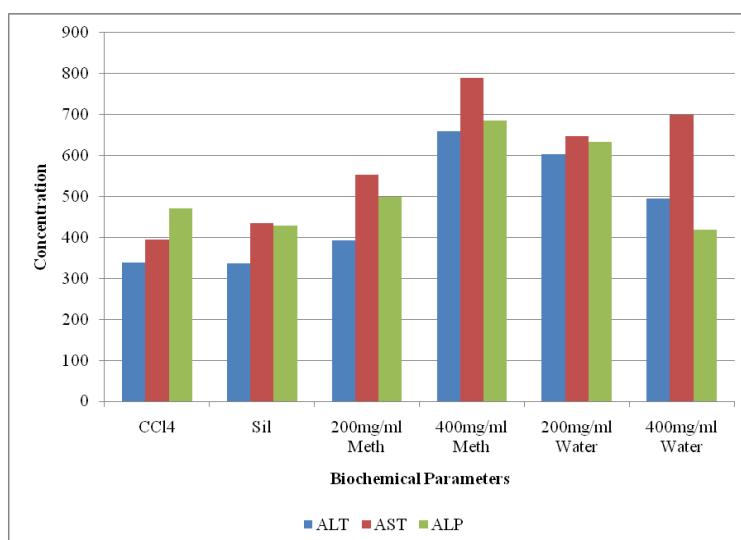
**Table 2.** Effect of methanolic and water extracts of *Fagonia cretica* L on biochemical parameters.

Biochemical Parameters	ALT (U/L)	AST (U/L)	ALP (U/L)
Normal Control	411 ± 95	562 ± 92	439 ± 29
$CCl_4$	338 ± 2.0	394 ± 40	471 ± 51
Silymarin	336 ± 18.2	435 ± 26	429 ± 1.3
Methanolic Extract (200 mg/ml)	393 ± 30	554 ± 29	499 ± 8.4
Methanolic Extract (400 mg/ml)	660 ± 82 <sup>**a-b</sup>	790 ± 93 <sup>**a-b</sup>	686 ± 59 <sup>***a**b</sup>
Water Extract (200 mg/ml)	604 ± 22 <sup>a-b</sup>	647 ± 72 <sup>*b</sup>	634 ± 27 <sup>**a**b</sup>
Water Extract (400 mg/ml)	496 ± 83	699 ± 38 <sup>a**b</sup>	419 ± 27

Values in Mean ± SEM, N=5

\*Significant at <sup>a</sup> $P < 0.05$ , \*\*highly significant at  $P < 0.01$ , and \*\*\*very high significant at  $P < 0.001$ . All values are compared with silymarin.

\*Significant at <sup>b</sup> $P < 0.05$ , \*\*highly significant at  $P < 0.01$ , and \*\*\*very high significant at  $P < 0.001$ . All values are compared with  $CCl_4$ .



**Figure 3.** Effect of methanolic and water extracts of *Fagonia cretica* L on biochemical parameters

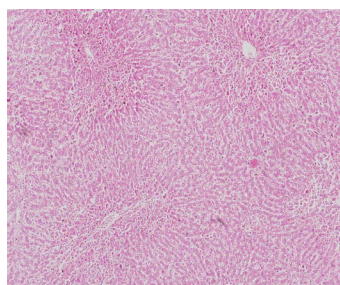
## Histopathology:

Histopathological changes occurred in liver after 48 hrs of  $CCl_4$ -injection, these changes were shown in **Figure 4** which indicated that the water extract slightly preserved the normal hepatocellular architecture from the damaging effects of  $CCl_4$  as compared to methanolic extract. The effects of Silymarin doses on liver sections showed multifocal tissue loss, perlobular necrosis and portal thrombosis, while,  $CCl_4$  doses showed inflammatory cells, necrosis, thrombosis in both central and portal vein and lobocentral necrosis (**Figure 5**).

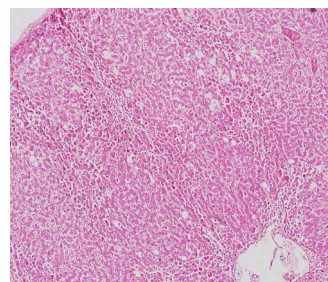
## DISCUSSION

Liver diseases remain one of the serious health problems. In the absence of reliable liver protective drugs in allopathic medical practices, herbs play a role in the management of various liver disorders in ethnomedical practices as well as in traditional systems of medicine [19]. Liver damage induced by  $CCl_4$  is commonly used as model for the screening of hepatoprotective activity. The rise in serum levels of SGPT, SGOT and ALP, has been attributed to the damaged structural integrity of the liver, because they are cytoplasmic in location and released into circulation after cellular damages. Carbon tetrachloride induces hepatotoxicity by metabolic activation; therefore, it selectively causes toxicity in liver cells maintaining semi normal metabolic functions.  $CCl_4$  metabolically activated by Cytochromes P450 (CYPs) in the endoplasmic reticulum to form a trichloromethyl free radical ( $CCl_3$ ), which combined with cellular lipids and proteins in presence of oxygen to induce lipid peroxidation [20]. Highly reactive trichloro free radicals formation directly attacks the poly unsaturated fatty acids of the endoplasmic reticulum and thus cause over production of SGOT, SGPT and ALP. In the present study, pre-treatment with methanolic and water extracts of *Fagonia cretica* L. (200 mg/kg and 400 mg/kg) attenuated the increases in the activities of SGOT, SGPT and ALP levels in blood serum of  $CCl_4$  induced hepatotoxicity. Silymarin is a known hepatoprotective compound obtained from *Silybum marianum* family (Asteraceae) is

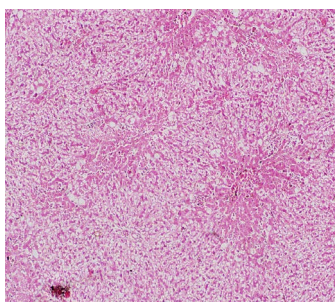
reported to have a protective effect on hepatic plasma membrane and possess multiple mechanisms of actions against different hepatotoxic agents. The study shows that the methanolic and water extracts of *Fagonia cretica* L. at higher dose (400 mg/kg) exhibited remarkable effect in lowering the high level of liver enzymes that occurred by CCl<sub>4</sub> compared to standard drug Silymarin, But the histopathological findings showed that the methanolic extract was superior to the water extract in protecting the hepatocellular architecture against CCl<sub>4</sub> induced toxicity.



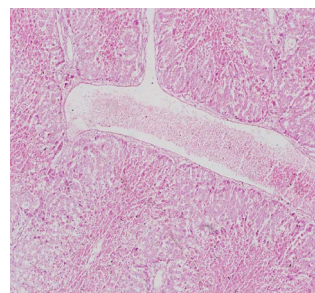
***Fagonia cretica*** Methanolic extract  
400mg×10tif.  
Liver Section: diffused fatty change, necrosis,  
portal thrombosis.



***Fagonia cretica*** Methanolic extract  
200mg×10tif.  
Liver Section: Portal thrombosis,  
Inflammatory cells,diffused fatty  
change,perilobular necrosis.

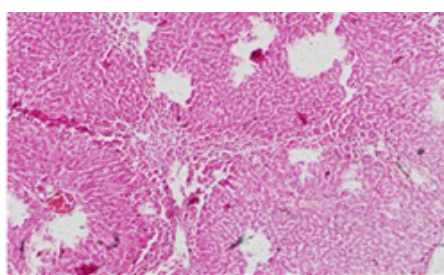


***Fagonia cretica*** water extract 400mg10×tif.  
Liver Section: diffused fatty change  
Centrilobular necrosis central hyperemia.

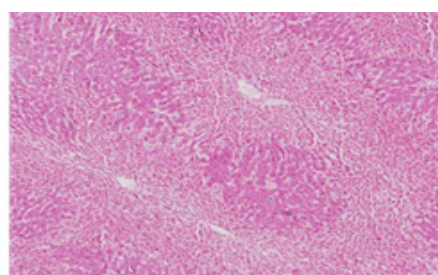


***Fagonia cretica*** water extract  
200mg×10tif.  
Liver Section: early stage of fatty  
change Centrilobular central  
hyperemia. portal hyperemia

**Figure 4.** Histopathological changes of methanolic and water extracts of *Fagonia cretica* L on liver sections.



***Fagonia cretica*** silymarin×10tif.  
Liver Section: Multifocal tissue loss, perilobular  
necrosis,portal thrombosis, no basement membrane of  
central vein.



***Fagonia cretica*** CCl<sub>4</sub>×10tif.  
Liver Section:Inflammatory cells, necrosis around central  
vein thrombosis in both central and portal vein, lobulocentral  
necrosis.

**Figure 5.** Histopathological changes of Silymarin, CCl<sub>4</sub> on liver sect

On the other hand, cytotoxicity was evaluated using Brine shrimp Lethality Test (BSLT), the *Fagonia cretica* L. extracts revealed significant cytotoxic activity against brine shrimps [21]. The LD<sub>50</sub> ranged from 0 to 100 µg/ml and those with <20 µg/ml were considered to be very active. Methanolic extract of *Fagonia cretica* L. showed LD<sub>50</sub>=77.2849 µg/ml. Therefore, the water extract which showed (LD<sub>50</sub>=1.7 µg/ml) was found to be very active against brine shrimp [21,22].

## CONCLUSION

In conclusion, preliminary phytochemical screening of extracts of *Fagonia cretica* L. showed the presence of some major bioactive compounds such as saponin, flavonoids and tannin, that can protect the liver. *Fagonia cretica* L. extracts showed cytotoxic effects. The methanolic and water extracts of *F. cretica* L. showed hepatoprotective activity. There is no previous study for hepatoprotective activity for *F. cretica* L. This plant can be considered as new biosource of hepatoprotective drugs.

## REFERENCES

1. WHO. World Health Organization Traditional Medicine Strategy, Geneva. 2013; 27.
2. ElHamidi A. Drug plants of the Sudan Republic in native medicine. *Planta Medica*. 1970; 3: 279-280.
3. ElKamali HM, El Khalifa KF. Treatment of malaria through herbal drugs in the Central Sudan. *Fitoterapia*. 1997; 68: 527-528.
4. Bassam ARH. Medicinal Plants (Importance and Uses). *Pharm Analy Acta*. 2012; 3:10.
5. Eddouks M, Moghrani M, Lemhadri A, Quahidi M, Jouad H. Ethnopharmacological survey of medicinal plants used for the treatment of diabetes mellitus, hypertension and cardiac diseases in the southeast region of Morocco. *J Ethnopharmacol*. 2002; 82:93-103.
6. WHO. World Health Organization Traditional Medicine Strategy. Geneva. 2002; 11.
7. UNIDO. Project for the Government of Sudan prepared by UNIDO industrial utilization of medicinal and aromatic plants in Sudan. 1996.
8. Phyllis E. Safety Evaluation and Hepatoprotective Activity of the Aqueous Stem Bark Extract of *Spathodea campanulata* Ph. D Thesis, KUMASI. 2012.
9. Vuyyuri B, Jyotsna GSL, Reshma T. A Review on Hepatoprotective Activity .In.*J Pharmaceut Sci Res*. 2014; 5: 690-702.
10. Mohamed STS, Madhusudhana CC, Ramkanth S, Rajan VST, Mahesh KK, Gauthaman K. Hepatoprotective Herbs: A Review. In *J Res Pharm Sci* 2010; 1:1-5.
11. Sajid B, Alia E, Rizwana K, Uzma S, Alamgeer, Hafiz MI. Phytochemical screening and antimicrobial activity of *Fagonia cretica* plant extracts against selected microbes. *J Pharm Res*. 2011; 4: 962-963.
12. El-Ghazali GBE, El-Tohami SM, El-Egami AAB. Medicinal plants of the Sudan. In: Medicinal plants of northern Kordofan. Omdurman Islamic University Printing and Publishing House, Omdurman. 1997.
13. Kabir Md S, Kaiser H, Latifa BZKM, Zahid A, Paritosh C. Effect of ardhabilva kvatha curna- an ayurvedic formulation on lipid profile after chronic administration. *Agri boil J N Amer*. 2010; 1: 812-816.
14. Razi MT, Muhammad HHBA, Taous K, Muhammad ZC, Muhammad TA, et.al. Antihaemorrhagic potentials of *Fagonia cretica* against *Naja naja karachiensis* (black Pakistan cobra) venom. *Nat Prod Res*. 2011; 25: 1902-1907.
15. Matthew L. Cytotoxic activity of *Fagonia cretica* against human breast cancer cells. Ph. D Thesis, Aston University, UK. 2012.
16. Alam EA. Morphological, phytochemical and biological Screening on three Egyptian species of *Fagonia*. *Acad Arena*. 2011; 3:18-27.
17. Rao KS, Mishra SH. Screening of anti-inflammatory and hepatoprotective activities of alantolactone isolated from the roots of *Inula racemosa*. *Ind Drugs*. 1997; 34: 571-5.
18. Carleton G, Harry A, Montgomery L. General histology procedure in Carleton's histology technique-5 E d .Oxford University press. 1980; 321:235.
19. Bhattacharya A, Ramanathan M, Ghosals, Bhattacharya SK. Effect of *Withania somnifera* glycowithanolides on iron-induced hepatotoxicity in rats. *Phytother Res*. 2000; 14: 568-70.
20. Padmaja R, Arun PC, Prashanth D, Deepak M, Amit A, Anjana M. Brine shrimp lethality bioassay of selected Indian medicinal plants. *Fitoterapia*. 2002; 73: 508-510.
21. Suresh K, Mishra H. Hepatoprotective activity of extracts from *Pergulariadaemia Forsk* against carbon tetrachloride induced toxicity in rats. *Pharmacog.Magaz*. 2007; 3:187-191.
22. Hala S, Haidar A, Abdel Wahab H. Cytotoxicity using Brine Shrimp Lethality Bioassay of *Tribulus terrestris* L. and *Fagonia cretica* L. extracts. 15<sup>th</sup> Symposium (NAPRECA), 7-10<sup>th</sup> Dec., Khartoum, Sudan. 2013.