

## Correlation of Clinical Finding with Ultrasound Diagnosis of Rotator Cuff Pathology.

Surendra U Kamath\*, Pawan Kumar Chajed, and Vivek P Nahar.

Department of Orthopaedics, Kasturba Medical College, Mangalore 5750003, Karnataka, India.

### Research Article

Received: 10/02/2014  
Revised: 26/02/2014  
Accepted: 08/03/2014

#### \*For Correspondence

Department of Orthopaedics,  
Kasturba Medical College,  
Mangalore 5750003,  
Karnataka, India  
Mobile: +91 9844275231

**Keywords:** Rotator cuff  
pathology, ultrasound,  
examination, correlation

#### ABSTRACT

The treatment of rotator cuff tears depends upon size and type, determined by examination and imaging. The ability of ultrasound to determine type and size of tear is helpful for treatment. The purpose of our study was to compare clinical examination with ultrasonographic findings of rotator cuff abnormality and to study the role of ultrasound in the diagnosis of rotator cuff pathology. This prospective study was conducted in 60 patients who had presented with shoulder pain due to either traumatic or degenerative cause. Patients with fracture or dislocation of shoulder, previous shoulder or upper limb surgery and malignancy were excluded from the study. All patients underwent a clinical examination followed by ultrasonography of the shoulder. In our study the sensitivity, specificity, a positive predictive value and negative predictive for diagnosing rotator cuff tears using ultrasound is 70.6%, 90.6%, 85.4% and 76.35% respectively for supraspinatus, infraspinatus, teres minor and subscapularis tendon injuries. In conclusion, Clinical examination has to be supplemented by imaging modality to plan treatment. Ultrasound is a noninvasive method to confirm the clinical diagnosis and help to diagnosis other potential clinical mimics of this injury. Also Static and Dynamic study of shoulder joint can be done under ultrasonography.

#### INTRODUCTION

The shoulder joint is a complex joint both anatomically and functionally. Its stability and concurrent multidirectional mobility is dependent on various structures. Rotator cuff is one of the main structures essential for dynamic and static stability as well as mobility of the joint.

The function of shoulder girdle requires the integrated motion of the sternoclavicular, acromioclavicular, glenohumeral and scapulothoracic joints. This motion is created by the delicate interaction of almost 30 muscles that control the shoulder system complex <sup>[1]</sup>.

One or more rotator cuff tendons may be inflamed from overuse, ageing (degeneration), a fall on outstretched hand or from a collision. Sports requiring repeated overhead arm motion or occupation requiring heavy lifting are prone for strain on Rotator cuff tendons and muscles. Normally tendons are strong but a long standing wearing down process may lead to tear.

Tears of rotator cuff are common cause of shoulder pain and disability. The treatment of rotator cuff tears depends upon size and type of tear, so clinical judgment and imaging modality is very important. The ability of ultrasonogram to determine type and size of tear is helpful to go ahead with treatment. The purpose of our study was to compare clinical examination with ultrasonographic findings of rotator cuff abnormality in patients with shoulder pain, to study the role of ultrasound in the diagnosis of rotator cuff pathology and to study the various patterns of rotator cuff injury.

#### MATERIALS AND METHODS

This prospective study was conducted after institutional ethics committee approval in sixty patients who had presented with shoulder pain due to either traumatic or degenerative cause. Patients with fracture or

dislocation of shoulder, previous shoulder or upper limb surgery and malignancy were excluded from the study. All patients underwent a clinical examination followed by ultrasonography of the shoulder. A thorough history and clinical examination performed by the experienced surgeon who will formulate a diagnosis on clinical findings.

Following a provisional diagnosis, all patients were subjected for ultrasonography using a 10 MHz frequency linear array transducer. All these ultrasonographic examinations were performed by two experienced musculoskeletal sonologists.

Using Chi square test sensitivity, specificity, positive predictive value and negative predictive value for supraspinatus, Infraspinatus, teres minor and Subscapularis injuries was calculated.

## RESULTS

Sixty patients who underwent ultrasonography after clinical diagnosis of rotator cuff pathology were included. Of these 60 cases 38 were males (63.3%) and 22 were females (36.7%). Right sided injury 42 (70%) was more than left side 18 (30%). The average age group was 40 years (range 18-65). Trivial Trauma is the major mode of injury followed by degeneration.

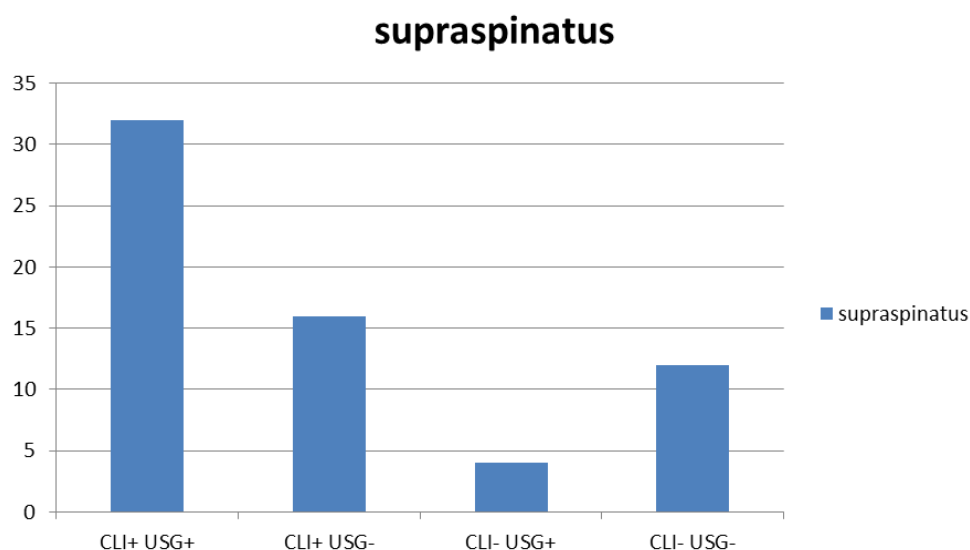
Forty eight supra supraspinatus tear were diagnosed clinically and USG showed thirty two supraspinatus tears. Of the forty eight clinically diagnosed cases thirty two showed corresponding lesions in ultrasound (true positives). Four case of diagnosed supraspinatus tear did not show in any clinical tests (false negative) and sixteen clinically diagnosed cases were not having any rotator cuff tear in ultrasound (false positive). So the sensitivity of clinical test in diagnosing supraspinatus tear is 66.7 % and specificity is 66.7 %. As per chi square test the P value will be 0.035. Eighteen cases were partial supraspinatus tear, of that nine were articular side tears, four were intra substance tear and five were bursal tears. 11 complete tears were present.

Eleven cases of Infraspinatus tear were present clinically and seven were having corresponding lesions in ultrasound (true positive). One case of Infraspinatus tear was missed clinically but picked up in USG (false negative). Four patients were clinically diagnosed of having Infraspinatus tear and found negative in USG (false positive). The p value for Infraspinatus tests was 0.001 as per Chi square test. So the sensitivity is 63.6% and specificity is 98%, positive predictive value and negative predictive value is 87.5% and 92.3% respectively.

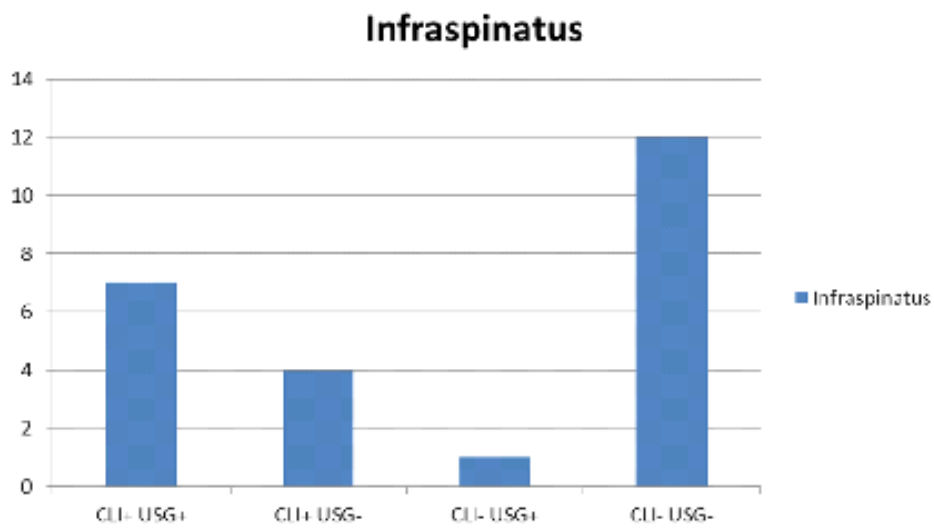
There were no true positive cases of teres minor tear. Eleven cases of false positive were present. Hence the sensitivity and positive predictive value and p value could not be calculated.

Subscapularis examination showed 5 cases clinically but only 4 were positive in ultrasound (true positive). One case was missed clinically but picked up by Ultrasound (false negative). The p value is highly significant 0.0002. Using Chi square test, sensitivity, specificity, positive predictive value and negative predictive value was calculated as 80%, 98.2%, 80% and 98.2% respectively.

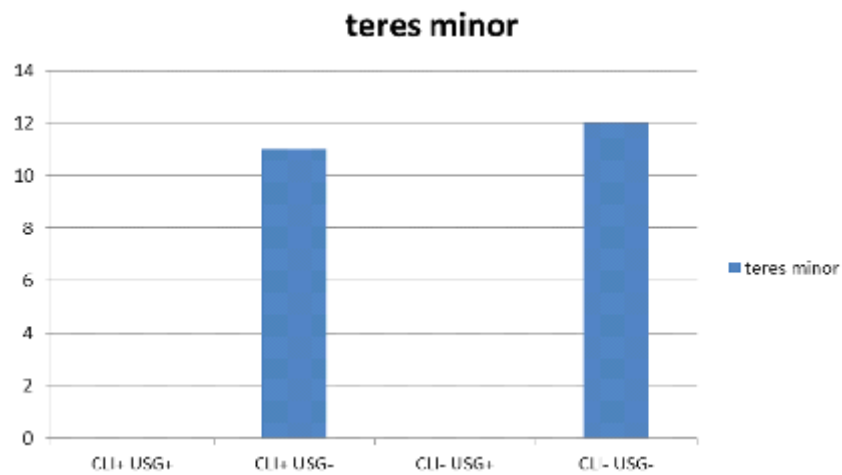
**Graph 1: Supraspinatus tendon injury diagnosis**



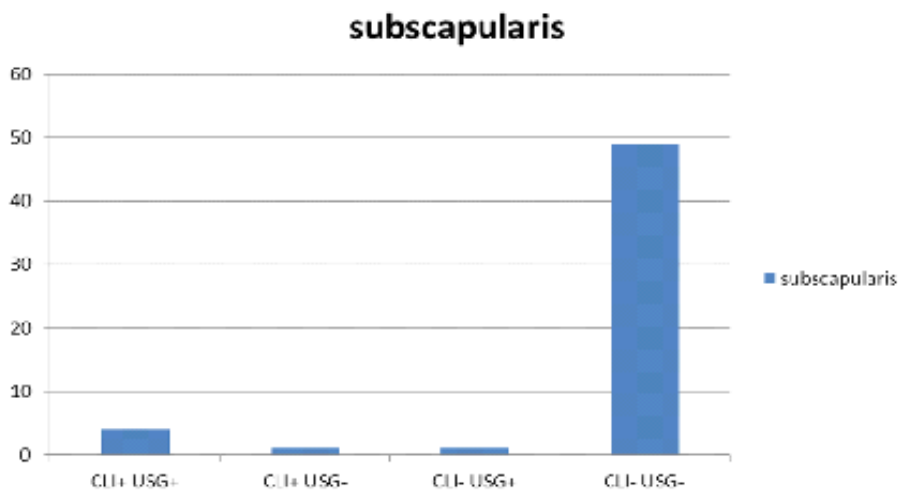
Graph 2: Infraspinatus tendon injury diagnosis



Graph 3: Teres minor tendon injury diagnosis



Graph 4: Subscapularis tendon injury diagnosis



## DISCUSSION

Out of sixty patients in our study, thirty eight (63.3%) were men and twenty two (36.7%) were women indicating men were predominantly involved as with study by Takagishi K et al.

Forty two (70%) cases were right sided involvement and eighteen (30%) had left sided involvement. Right sided involvement is more common, may be due to their right handedness [2].

Trivial trauma during daily activities accounted nearly eighty percent of the injuries, remaining were trauma due to fall and insidious onset due to degeneration. This finding was similar to previous studies by Neer et al [3].

On clinical examination forty eight (80%) cases were diagnosed to have injury to supraspinatus tendon, eleven cases(18.3%) were Infraspinatus injuries , eleven cases (18.3%) of teres minor injury and five cases( 8.3%) of subscapularis injury. Therefore it can be stated that supraspinatus is the most commonly involved tendon in rotator cuff injuries [4, 5].

All cases underwent ultrasound examination of the involved shoulder. In the ultrasound thirty six cases had supraspinatus injury, eight cases of Infraspinatus injury and five cases of subscapularis injury. No teres minor tendon injury was found. This suggests that supraspinatus is the most commonly torn tendon in rotator cuff injuries, which was also observed in the study by Ziegler et al study [5].

In our study the sensitivity, specificity, a positive predictive value and negative predictive for diagnosing rotator cuff tears using ultrasound is 70.6%, 90.6%, 85.4% and 76.35% respectively when compared to the study by Ziegler et al which showed the following result 99.6%, 85.7% , 99.6% and 85.7% respectively [5].

Out of the thirty six cases ( true positive) of supraspinatus torn tendon identified by ultrasound eighteen cases( 50%) had partial tear showing hypoechoic fibre , discontinuity within the tendon and eleven cases( 30.5%) having full thickness tear showing non visualization of the tendon or fibre discontinuity from humeral head. The remaining seven cases (19.5%) showed features of tendinitis. Out of sixteen false positive cases fourteen cases showed no ultrasound abnormality. Out of the four false negative cases, two cases had partial tear on USG, since the patient consulted at 2 months after the trauma and in healing stage of disease and the remaining two cases had tendinitis. Four case of false positive tear was found in Infraspinatus tendon but in USG examination showed no tear, only inflammation was found. Two cases of false positive case were found that is attributed to acute pain due to nearby supraspinatus tear.

Clinically eleven cases of teres minor cases were found. None of the cases were ultrasound positive. Hence specificity and positive predictive value could not be calculated and correlated with other studies. It was seen that most of the cases were associated with infraspinatus tear.

Clinically four cases of subscapularis tendon tears were confirmed by ultrasound, one false positive and one false negative case was found. In our study incidence of subscapular tendon tear was 8.33%.Most of the subscapular tears were complete tears and accounting to 80% of the subscapular tears. Were as the study by Gerber et al showed partial tear is more common, it may be due to sample size is small. And the remaining 20% were full thickness tears. Most the subscapularis tear were isolated tears and trauma mainly being the cause.

The results thus confirm the usefulness of Ultrasound Imaging in the diagnosis of rotator cuff injuries. However our study had certain shortcomings. Although various authors suggest MRI as the gold standard for diagnosing the rotator cuff injuries, hence estimation of tears tendon may not be precise but studies have shown MRI results are similar to ultrasound for detection of tears. The limitation of this study is that no arthroscopic and MRI confirmations of the lesions were done [6, 7, 8]. A large sample random controlled double blinded study can be more conclusive. Measuring tear size was not analyzed and ultrasound with more resolution will increase the accuracy of rotator cuff tears and mainly its operator dependent [9, 10, 11, 12].

## CONCLUSION

We conclude that clinical examination has low sensitivity and specificity for detection of rotator cuff tears hence less reliable method of diagnosing rotator cuff tears and clinical examination needs to be supplemented by imaging modality to plan treatment.

We also conclude that ultrasound is a noninvasive method to confirm the clinical diagnosis and help to diagnosis other potential clinical mimics of this injury. Static and dynamic study of shoulder joint can be done with ultrasonography. It is important to observe that partial thickness tears are better picked up by ultrasound.

## ACKNOWLEDGEMENTS

We acknowledge the support and help from Kasturba Medical College, Mangalore and Manipal University in performing this study.

## REFERENCES

1. Hyung Bin Park, Atsushi Yokata, Harpreet S Gill, George El Rassi and Edward G McFarland Diagnostic Accuracy of Clinical Tests for Different Degrees of Subacromial Impingement Syndrome. *J Bone Joint Surg.* 2005;879(A): 1446-1455.
2. Yamamoto A, Takagishi K et al. Prevalence and risk factors of a rotator cuff tear in the general population. *J Shoulder Elbow Surg.* 2010;19(1):116-20
3. Neer CS II: Anterior Acromioplasty for the chronic impingement syndrome in the shoulder: A preliminary Report. *J. Bone Joint Surg,* 1972;54(A); 41-50
4. Mall NA, Lee AS, Chahal J, Sherman SL et al. An evidenced-based examination of the epidemiology and outcomes of traumatic rotator cuff tears. *Arthroscopy.* 2013;29(2):366-76.
5. Ziegler DW. The use of in-office, orthopaedist-performed ultrasound of the shoulder to evaluate and manage rotator cuff disorders. *J Shoulder Elbow Surg* 2004;13:291-7.
6. Teefey SA, Rubin DA, Middleton WD, Hildebolt CF, Leibold RA, Yamaguchi K. Detection and quantification of rotator cuff tears. Comparison of ultrasonographic, magnetic resonance imaging, and arthroscopic findings in seventy-one consecutive cases *J Bone Joint Surg.* 2004;86(A):708-16.
7. Bryant L, Shnier R, Bryant C, Murrell GA. A comparison of clinical estimation, ultrasonography, magnetic resonance imaging, and arthroscopy in determining the size of rotator cuff tears. *J Shoulder Elbow Surg.* 2002;11:219-24
8. Iannotti JP, Ciccone J, Buss DD, Visotsky JL, Mascha E, Cotman K, et al. Accuracy of office-based ultrasonography of the shoulder for diagnosis of rotator cuff tears. *J Bone Joint Surg.* 2005; 87(A):1305-11.
9. Al-Shawi A, Badge R, Bunker T. The detection of full thickness rotator cuff tears using ultrasound. *J Bone Joint Surg.* 2008; 90(Br):889-92.
10. Kim HA, Kim SH, Seo YI. Ultrasonographic findings of painful shoulders and correlation between physical examination and ultrasonographic rotator cuff tear. *Mod Rheumatol.* 2007;17:213-219.
11. E Naredo, P Aguado et al. Painful shoulder: comparison of physical examination and ultrasonographic findings. *Ann Rheum Dis.* 2002;61:132-136
12. S A Teefay et al. Ultrasonography of the rotator cuff. A comparison of ultrasonographic and arthroscopic findings in 100 consecutive cases. *J Bone Joint Surg.* 2000;82(A):498-504.