

## Clumping of the Nuclei Material of Pyramidal Cells of Adult Wistar Rats Following Oral Administration of Monosodium Glutamate.

Musa MA<sup>1\*</sup>, and Sunday AM<sup>2, 3</sup><sup>1</sup> Department of Anatomy, College of Health Sciences, Usmanu Danfodiyo University, Sokoto.<sup>2</sup> Department of Human Anatomy, Faculty of Medicine, Ahmadu Bello University, Zaria.<sup>3</sup> Stereology and Electron Microscopy Research Laboratory, Danish Neuroscience Center, University Hospital, Aarhus, Denmark.

## Article

Received: 25/11/2012

Revised: 07/12/2012

Accepted: 01/02/2013

**\*For Correspondence**

Department of Anatomy, College of Health Sciences, Usmanu Danfodiyo University, Sokoto.

Email:

musa.muhammadawwal@gmail.com

Phone: +2348065297577.

**Keywords:** Monosodium glutamate, chromatolysis, pyramidal cells, Wistar rats.**ABSTRACT**

Monosodium Glutamate (MSG) is the crystalline sodium salt of glutamate used primarily to preserve or enhance the flavor of food. Studies have shown that MSG causes damage in brain cells of animals like rats and rabbits. This research was conducted to investigate the effect of MSG on the histology of the pyramidal cells of the cerebral cortex (frontal lobe) of Wistar rats. A total of 15 adult Wistar rats were procured. The animals were divided into three (3) groups A, B and C with each group comprising of 5 animals. Group A – (the control group) was administered with 1 ml of distilled water while experimental groups B and C were orally administered with 2mls and 3mls of 2g/10ml MSG for a period of 14 days. After which the rats were sacrificed and the tissues were processed using the routine histological procedures and stained with H&E method. Histological findings revealed clumping and elongation of the nuclei material of pyramidal cells in the frontal lobe of the experimental groups, with higher clumping and elongation observed in group C which was administered higher dose of monosodium glutamate.

**INTRODUCTION**

Monosodium Glutamate (MSG) popularly known as “Ajino-moto” –marketed by West African Seasoning Company Limited or “Vedan” –marketed by Mac & Mei (Nig) Limited is a crystalline sodium salt of glutamic acid used in cooking primarily to enhance the flavour of food or as a preservative<sup>[1]</sup>. Monosodium glutamate is recognized as a standard of identity ingredient in several commercial food preparations. It is principally used in the preparation of canned and dried soups; some meat, fish products, vegetables, fowl etc. it is the so-called “Secret Ingredient” used by many of the famous restaurant and hotel chefs.

Though MSG improves taste stimulation and enhances appetite, reports indicate that it is toxic to human and experimental animals<sup>[2]</sup>. The safety of monosodium glutamates usage has generated much controversy locally and globally<sup>[3]</sup>. In Nigeria, most communities and individuals often use MSG as a bleaching agent for the removal of stains from clothes. There is a growing apprehension that its bleaching properties could be injurious to health. Despite evidence of negative consumer response to MSG, reputable international organizations and nutritionists have continued to endorse MSG reiterating that it has no adverse reactions in humans. Notably of such is the Directorate and Regulatory Affairs of Food and Drug Administration and Control (FDA&C) in Nigeria, now NAFDAC in 1992 expressed the view that MSG is not injurious to health<sup>[4]</sup>.

MSG improves the palatability of meals and thus influences the appetite centre positively with its resultant increase in body weight<sup>[5,6,7]</sup>. Though MSG improves taste stimulation and enhances appetite, reports indicate that it is toxic to human and experimental animals<sup>[2]</sup>. MSG has a toxic effect on the testis by causing a significant oligozoospermia and increase abnormal sperm morphology in a dose-dependent fashion in male Wistar rats<sup>[8]</sup>. It has been implicated in male infertility by causing testicular

hemorrhage, degeneration and alteration of sperm cell population and morphology [9]. It has been reported that MSG has neurotoxic effects resulting in brain cell damage [1]. Apart from its application in the food industry as a flavor enhancer, it has been reported in the United States to have found use in medicine [10].

As early as 1957, Lucas and Newhouse [11] noticed that severe retinal lesions could be produced in suckling mice (and to some extent in adult mice) by a single injection of free glutamic acid. Studies confirming their findings using neonatal rodents [12, 13, 14] and adult rabbits [15] followed shortly thereafter. Seen were lesions in the pre-optic and arcuate nuclei of the hypothalamic region and roof of the 3<sup>rd</sup> ventricle and scattered neurons in the nuclei tubercles. No pituitary lesion were even bad sub-commissural and sub-fornical organs exhibited intra cellular edema and neuronal necrosis [13].

MSG is absorbed very quickly into the blood stream as compared to glutamic acid. People develop headache after eating foods containing MSG. this is called "Chinese- restaurant- syndrome." [16]. Martinez et. al., (2002) observed that neonatal administration of a MSG induces reactivity of the astrocytes and microglia cells in the fronto-parietal axis cortex which is characterized by hyperplasia and hypertrophy [17]. Also previous studies have shown that neonatal administration of a dosage of MSG to the newborn rats caused excitotoxic damage of the glial cells of the adult brain of Wistar rat [18]. According to Ekpo (2005) reported the adverse effect of MSG on the hypothalamic lesion which corresponds to human experience on severe headache of the users of monosodium salt [19]. Experiment on young mice, rats, rabbits, guinea pigs and rhesus monkeys showed that MSG caused damage to brain cells. This was found in both infant and adult animals, but adult were only susceptible in much higher doses. Another experiment showed that whereas exposure to MSG caused mature but not young, brain cells to die, the action was dependent on a lack of calcium [10]. In guinea pigs subcutaneous administration of MSG of dose 4g/kg, an increase in glial cells was shown. Vascularisation of cells in arcuate nuclei and some evidence of cell necrosis were observed. The effect of the lesions was no way comparable to the effect seen in the hypothalamus of mice treated with same doses [20].

Samuels, (1999) reported that MSG has neurotoxic effects resulting in brain cell damage, retinal degeneration and endocrine disorders and some pathological conditions such as addiction, stroke, epilepsy, brain trauma, neuropathic pain, schizophrenia, anxiety, depression, Parkinson's disease, Alzheimer's disease, Huntington's disease, and amyotrophic lateral sclerosis [21]. MSG has also been reported to have a deleterious effect on the neurons of the intracranial visual relay centre and this may probably have some adverse effects on visual sensibilities by its deleterious effects on the cells of the superior colliculus (SC) of adult Wistar rats [1].

Pyramidal cells on the other hand, are among the largest neurons in the brain. Both in humans and rodents, pyramidal cell bodies (somas) average around ~ 20µm [22]. Pyramidal dendrites typically range in diameter from half a micrometer to several micrometers. The length of a single dendrite is usually several hundred micrometers. Due to branching, the total dendritic length of a pyramidal cell may reach several centimeters. The pyramidal cell's axon is often even longer and extensively branched, reaching many centimeters in total length [22]. Pyramidal neurons in the prefrontal cortex are implicated in cognitive ability. In mammals, the complexity of pyramidal cells increases from posterior to anterior brain regions. The degree of complexity of pyramidal neurons is likely linked to the cognitive capabilities of different anthropoid species [22, 23]. Because the prefrontal cortex receives inputs from areas of the brain that are involved in processing all the sensory modalities, pyramidal cells within the prefrontal cortex may process many different types of inputs. Pyramidal cells may play a critical role in complex object recognition within the visual processing areas of the cortex [23]. Pyramidal cells are a type of neuron found in areas of the brain including cerebral cortex, the hippocampus, and in the amygdala. Pyramidal cells are the primary excitation units of the mammalian prefrontal cortex and the corticospinal tract. Pyramidal neurons were first discovered and studied by Santiago Ramón Y. Cajal [23, 24]. Since then, studies on pyramidal neurons have focused on topics ranging from neuroplasticity to cognition [23, 24]. This work was carried out to investigate the effects of MSG on the histology of the pyramidal cells and in particular to check if chromatolysis was precipitated in the cells as a result of ingestion of monosodium glutamate.

## MATERIALS AND METHODOLOGY

### Animal Procurement

A total of 15 adult Wistar rats (*Rathus Norvegicus*) of both sexes weighing between 170–250g were procured from the Animal House of the Human Anatomy Department. Ahmadu Bello University, Zaria. They were caged in a room, maintained at room temperature for a period of 2 weeks to acclimatize. They were kept under uniform husbandry condition and were fed with growers' mash and water. The animals were divided into 3 group of A, B and C. Each group comprising of 5 animals.

### Ethical Approval

Ethical Clearance was obtained from the Ahmadu Bello University Research & Ethical Committee.

The monosodium glutamate (3g/sachet containing 99+% of MSG) was obtained from Dan Baba Grocery stores, Samaru, Zaria, Kaduna State.

#### Experimental Design

Group A served as the control group while groups B and C served as the treatment groups. The experimental groups B and C were orally administered with 2mls and 3mls of 2g/10ml of MSG respectively for 14 days during which the animals were observed. Routine histological techniques. The above MSG doses were chosen and extrapolated in this experiment based on the indiscriminate use here in the Northern part of Nigeria due to its palatability, and previous work done with this additive [1, 26, 27]. The two doses were orally administered to each group daily.

#### Animal Sacrifice

The animals were sacrificed on the fifteenth day, after suffocation in chloroform and the brain tissues were quickly obtained and fixed in 10% Bouins fluid, this was carried out for all the groups. After the fixation the brain was dissected to get the frontal lobe of the cerebral cortex.

#### Histological Procedure

The tissues were transferred to automatic tissue processor where they undergo dehydration in each of the ascending grades of alcohol, 70%, 90%, 95% and absolute alcohol for 2 changes each. After which the tissues were cleared in chloroform and embedded in paraffin wax. Serial sections of 5 microns thick were obtained from a rotatory microtome. The deparaffinized sections were routinely stained with Haematoxyline and Eosin method [25], and viewed under the light microscope.

#### Photomicrographs

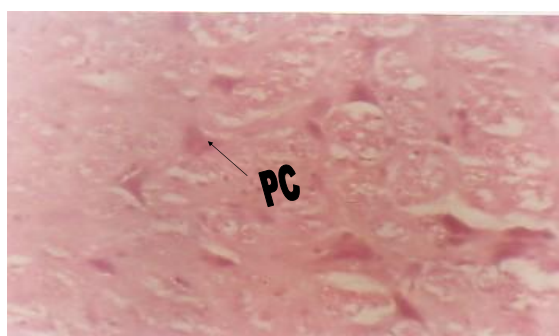
The photomicrographs of the desired sections were obtained using digital photographic microscope.

### RESULTS

#### Control Group A

The animals in the control group (Group A) were not administered MSG, but were fed with normal diet and had free access to water, thus their photomicrographs showed distinct appearance of the pyramidal cells in their frontal lobe (Fig.1). The pyramidal cells showed normal histological features, illustrating a well defined cell body, with a single axon, and multiple basal dendrites observed.

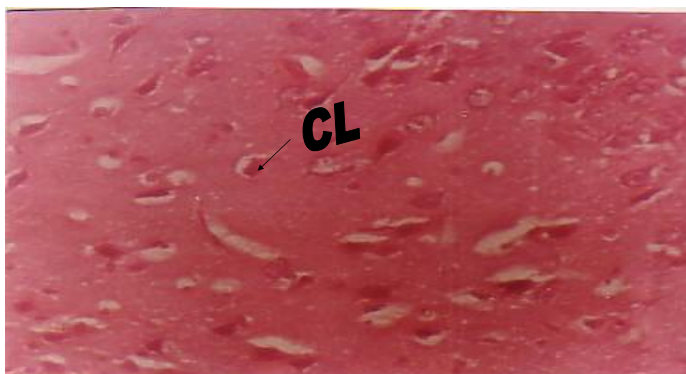Fig.1



- **GROUP A:** (H&E Stain)-The pyramidal cells appeared distinct. **PC**-pyramidal cell. Mg\*250

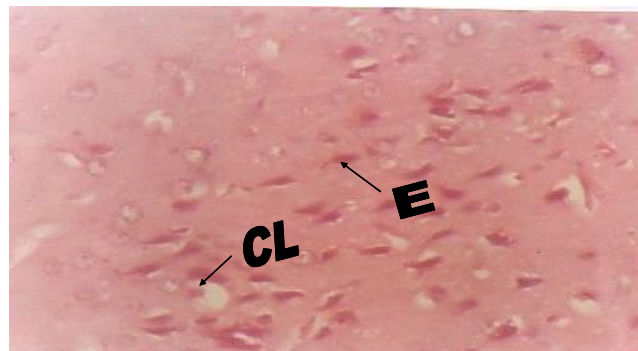
## Experimental Groups B and C

The photomicrographs of the animals in the experimental groups (Group B and C) who were administered with 2mls and 3mls of 2g/10ml MSG revealed clumping of the nuclei material of the pyramidal cells with the nuclei material pushed to the periphery of the cell body (Fig. 2 and 3). With higher clumping and elongation of the cellular material seen in Group C (Fig.3). And as such, the distinctive features of the pyramidal cell are missing even though not completely but to a great extent. This shows that chromatolysis was precipitated in the pyramidal cells of the Wistar rats and the level of pronouncement was dose dependent.



**GROUP B:** (H&E Stain)- the nuclei materials are seen to be clumped and pushed to the periphery of the cell. **CL-** clumping of pyramidal cell. Mg\*250

Fig.2



**GROUP C :** (H&E Stain)- This micrograph showed both clumping (**CL**) of nuclei materials as well as Elongation (**E**) of the pyramidal cells. Mg\*250.

Fig.3

## DISCUSSIONS

The results of the Haematoxylin and Eosin staining (H & E) reactions showed some clumping of the nuclei material as well as elongation of the cell body of the pyramidal cells and this indicates degenerative and atrophic changes. The result from this study agrees with previous studies <sup>[1,20, 25]</sup> where evidence of neurotoxicity such as distortions of the cyto-architecture of the cerebellum were observed and reported. With biochemical and histological neurodegenerative effects seen in Wistar rats due to consumption of MSG <sup>[25]</sup>. And by extension, these neurodegenerative effects may affect the functions of the cerebellum and this is probably the cause of the uncoordinated and tremors observed in the MSG treated Wistar rats as reported <sup>[1]</sup>.

Degenerative and atrophic changes such as chromatolysis of the soma were observed in some parts; these were more pronounced in the group C that received 3mls of 2g of MSG.

There were marked elongations of the nuclei material appearing in the soma of the pyramidal cells of MSG treated rats. The increase in clumping of the nuclei material in the treatment groups as reported in this study may have been as a result of cellular proliferation caused by the daily oral administration of MSG <sup>[1,5]</sup>.

Due to observed distortions and elongations of the cell body of the pyramidal cells, the cognitive function of the prefrontal cortex may have been highly affected as a result of probable toxic effect of MSG. In fact, even the visual processing area of the cortex might have been affected since pyramidal cells are known to play a very critical role in complex object recognition within the visual processing areas of the cortex <sup>[15, 23]</sup>

It may be inferred from this present results that higher dose and prolonged administration of MSG resulted in neurodegenerative changes as observed in the histology of the pyramidal cells of adult Wistar rats. The actual mechanism by which MSG induced cellular degeneration observed in this study needs further investigation.

Degenerative changes have been reported to result in cell death <sup>[28]</sup>.

## CONCLUSION

From this study, it can be deduced that MSG treated adult Wistar rats suffered clumping of nuclei material and elongation of the soma of pyramidal cells of their frontal lobes following the administration of 2mls of 2g/10ml and 3mls of 2g/10ml per day of MSG to adult Wistar rats. Thus, chromatolysis was precipitated. However, the clumping and elongation effect was more pronounced in those in Group C that received 3mls of 2g/10ml of MSG.

It is recommended that further studies be carried out to corroborate these findings.

#### ACKNOWLEDGMENT

We sincerely acknowledge the efforts of the staff of the Histology Laboratory of the Department of Human Anatomy, Faculty of Medicine, Ahmadu Bello University, Zaria.

#### REFERENCES

1. Eweka AO, Adjene JO. Histological studies of the effects of monosodium Glutamate on the medial geniculate body of adult Wistar rat. *Electron J Biomed.* 2007; 22 :9-13.
2. Belluardo M, Mudo G, Bindoni M. Effect of early destruction of the mouse arcuate nucleus by MSG on age dependent natural killer activity: *Brain Res.* 1990;534:225-333.
3. Biodun D, Biodun A. A spice or poison? Is monosodium glutamate safe for human consumption? *National Concord Newspaper.* 1993; 4:5.
4. Okwuraiwe PE. The role of Food and Drug Administration and Control (FDA&C) in ensuring the safety of food and food ingredients: A symposium held at Sheraton Hotel, Lagos. 1992 Sep 1st;6-15.
5. Rogers PP, Blundell JE. Umani and appetite: Effects of monosodium glutamate on hunger and food intake in human subjects. *Physiol Behav.* 1990; 48 (6):801-804.
6. Iwase M, Yamamoto M, Iino K, Ichikawa K, Shinohara N, Yoshinari F. Obesity induced by neonatal monosodium glutamate treatment in spontaneously hypertensive rats: an animal model of multiple risk factors. *Hypertens Res.* 1998;43:62-28.
7. Gobatto CA, Mello MA, Souza CT, Ribeiro IA. The monosodium glutamate (MSG) obese rat as a model for the study of exercise in obesity. *Res Commun Mol Pathol Pharmacol.* 2002;(2):116-128.
8. Onakewhor JUE, Oforofuo IAO, Singh SP. Chronic administration of Monosodium glutamate Induces Oligozoospermia and glycogen accumulation in Wistar rat testes. *Africa J Reprod Health.* 1998;2(2):190-197.
9. Oforofuo IAO, Onakewhor JUE, Idaewor PE. The effect of chronic admin of MSG on the histology of the Adult Wistar rat testes. *Biosc Resch Comms.* 1997;9(2):6-15.
10. Adelaja, AO, Nayga Jr. RM, Schilling BJ, Tank KR. Understanding the challenges facing the food manufacturing industry. *Journal of Food Products Marketing.* 2000;6 (2): 35 - 55.
11. Lucas DR, Newhouse JP. The toxic effect of sodium-L-glutamate on the inner layers of the retina. *AMA Arch Ophthalmol.* 1957; 58: 193-201.
12. Potts, AM, Modrell RW, Kingsbury C. Permanent fractionation of the electroretinogram by sodium glutamate. *Am J Ophthalmol.* 1960;50: 900-907.
13. Freedman JK, Potts AM. Repression of glutaminase I in rat retina by administration of sodium L-glutamate. *Invest Ophthalm.* 1963;2: 252.
14. Potts AM. Selective action of chemical agents on individual retinal layers. In: *Biochemistry of the retina.* Graymore, C.N., Ed. New York: Academic Press, p. 155-161; 1965.
15. Hamatsu, T. Experimental studies on the effect of sodium iodate and sodium L-glutamate on ERG and histological structure of retina in adult rabbits. *Acta Soc Ophthalmol Jpn.* 1984;68: 1621-1636. (Abstract)
16. Sollman T. *A Manual of Pharmacology*, 8<sup>th</sup> ed. W.B. Sanders Co., Philadelphia, 1957.
17. Martinez-Contreras A, Huerta M, Lopez-Perez S, Garcia-Estrada J, Luquin S, Beas ZC. Astrocytic and microglia cells reactivity induced by neonatal administration of glutamate in cerebral cortex of the adult rats. *J Neurosci Res.* 2002;67:200-210.
18. Keith ME, Michael A. Manganese neurotoxicity and glutamate-GABA interaction. *Neurochem Intl.* 2003;43 (4-5): 475-480.
19. Ekpo AJ, Jimmy EO. Nutritional effect of spices from roasted chicken and beef meat consumption. *Pak J Nutr.* 2005; 4(6):428-430.
20. Golberg, L. Unpublished report from the Institute of Experimental Pathology and Toxicology, Albany Medical College. Submitted to WHO in 1973.
21. Samuels A. The Toxicity/Safety of MSG: A study in suppression of information. *Acctabil Resch.* 1999;6(4):259-310.
22. Megías M, Emri Z, Freund TF, Gulyás AI. Total number and distribution of inhibitory and excitatory synapses on hippocampal CA1 pyramidal cells. *Neuroscience.* 2001;102(3):527-40.
23. Elston GN. Cortex, cognition and the cell: new insights into the pyramidal neuron and prefrontal function. *Cereb Cortex.* 2003;13 (11): 1124-38.
24. García-López P, García-Marín V, Freire M. Three-dimensional reconstruction and quantitative study of a pyramidal cell of a Cajal histological preparation. *J Neurosci.* 2006;26 (44): 11249-52.
25. Drury RAB, Wallington EA, Cameron R. *Carleton's Histological Techniques.* 4th ed. NY. USA: Oxford University Press, p. 279-280; 1967.
26. Alao OA, Ashaolu JO, Ghazal OK, Ukwanya VO. Histological and biochemical effects of monosodium glutamate on the frontal lobe of adult Wistar rats. *Int J Biomed Health Sci.* 2010;6 (4):197-203.
27. Eweka AO, Om'Iniabohs FAE. Histological Studies of the Effects of Monosodium Glutamate on the Superior Colliculus of Adult Wistar Rats: *The Internet J Neurol.* 2007;8:2.

28. Wyllie AH. Glucocorticoid-induced thymocyte apoptosis is associated with endogenous endonuclease activation. *Nature*. 1980; 284:555-556.